Chapter 6

The Glaucomas

Introduction

Physiology of aqueous production
Anatomy of aqueous outflow
Physiology of aqueous outflow
Intraocular pressure
Classification of the glaucomas

Tonometry

Goldmann applanation tonometry
Other tonometers

Gonioscopy

Introduction
Goniolenses
Interpretation of gonioscopic findings

The optic nerve head

Applied anatomy
Appearance of the optic nerve head
Glaucomatous damage

Perimetry

Definitions
Perimetric principles
Potential sources of error
General principles of automated perimetry
Humphrey perimeter
Visual field defects in glaucoma

Ocular hypertension

Introduction
Management

Primary open-angle glaucoma

Introduction
Clinical features
Screening
Management

Normal-tension glaucoma

Introduction
Clinical features
Management
Differential diagnosis

Primary angle-closure glaucoma

Introduction
Latent angle-closure glaucoma
Intermittent angle-closure glaucoma
Acute congestive angle-closure glaucoma
Postcongestive angle-closure glaucoma
Chronic angle-closure glaucoma
Plateau iris configuration and syndrome

Pseudoexfoliation syndrome and glaucoma

Pseudoexfoliation syndrome
Pseudoexfoliation glaucoma

Pigment dispersion syndrome and pigmentary glaucoma

Pigment dispersion syndrome
Pigmentary glaucoma

Neovascular glaucoma

Introduction
Rubeosis iridis
Secondary neovascular open-angle glaucoma
Secondary neovascular angle-closure glaucoma

Inflammatory glaucomas

Introduction
Secondary angle-closure glaucoma with pupil block
Secondary angle-closure glaucoma without pupil block
Secondary open-angle glaucoma
Glaucoma in Fuchs uveitis syndrome
Posner–Schlossman syndrome

Miscellaneous secondary glaucomas

Phacolytic glaucoma
Phacomorphic glaucoma
Red cell glaucoma
Post-traumatic angle recession glaucoma
Ghost cell glaucoma
Iridocorneal endothelial syndrome
Iridoschisis

Congenital glaucomas

Primary congenital glaucoma
Iridocorneal dysgenesis
Glaucoma in phacomatoses

Glaucoma drugs

Beta-blockers
Sympathomimetics
Miotics
Prostaglandin derivatives
Carbonic anhydrase inhibitors
Hyperosmotic agents

Lasers in glaucoma

Argon laser trabeculoplasty
Diode laser trabeculoplasty
Nd:YAG laser iridotomy

Trabeculectomy

Introduction
Surgical technique
Postoperative complications
Failure of filtration
Adjuctive antimetabolites

Artificial drainage shunts

Cyclodestructive procedures

INTRODUCTION

Physiology of aqueous production

1. **Active secretion**: approximately 80% is produced by the non-pigmented ciliary epithelium as a result of an active metabolic process that depends on several enzymatic systems, especially the Na+/K+ ATPase pump which secretes Na+ ions into the posterior chamber. Aqueous secretion is diminished by factors that inhibit active metabolism such as hypoxia and hypothermia but it is independent of the level of intraocular pressure (IOP).
2. **Passive secretion**: the remaining 20% of aqueous is produced by ultrafiltration and diffusion which are dependent on the level of blood pressure in the ciliary capillaries, the plasma oncotic pressure and the level of IOP. If the IOP is very high the rate of aqueous secretion will therefore diminish. Aqueous secretion is also diminished by the following:
   (a) ***Drugs*** such as beta-blockers, sympathomimetics and carbonic anhydrase inhibitors.
   (b) ***Cyclodestructive procedures.***
   (c) ***Ciliary body shutdown*** which may be caused by: detachment of the ciliary body, inflammation of the secretory ciliary epithelium associated with iridocyclitis, and retinal detachment.

Anatomy of aqueous outflow

1. **The trabeculum** (trabecular meshwork) (Figure 6.1) is a sieve-like structure through which 90% of the aqueous humour leaves the eye. It consists of the following three portions (Figure 6.2):
   (a) ***The uveal meshwork*** is the innermost portion which consists of cord-like meshes that extend from the root of the iris to Schwalbe line. The intertrabecular spaces are relatively large and offer little resistance to the passage of aqueous.
   (b) ***The corneoscleral meshwork*** forms the larger middle portion, which extends from the scleral spur to Schwalbe line. The meshes are sheet-like and the intertrabecular spaces are smaller than in the uveal meshwork.
   (c) ***The endothelial (juxtacanalicular) meshwork*** is the narrow outer part of the trabeculum which links the corneoscleral meshwork with the endothelium of the inner wall of Schlemm canal. The juxtacanalicular tissue is very important because it offers the major proportion of normal resistance to aqueous outflow.
2. **Schlemm canal** is a circumferential channel bridged by septa. The inner wall of the canal is lined by irregular spindle-shaped endothelial cells which contain infoldings (giant vacuoles). The outer wall of the canal is lined by smooth flat cells and contains the openings of the collector channels which leave Schlemm canal at oblique angles and connect either directly or indirectly with episcleral veins.

Figure 6.1 Scanning electron micrograph of the trabecular meshwork

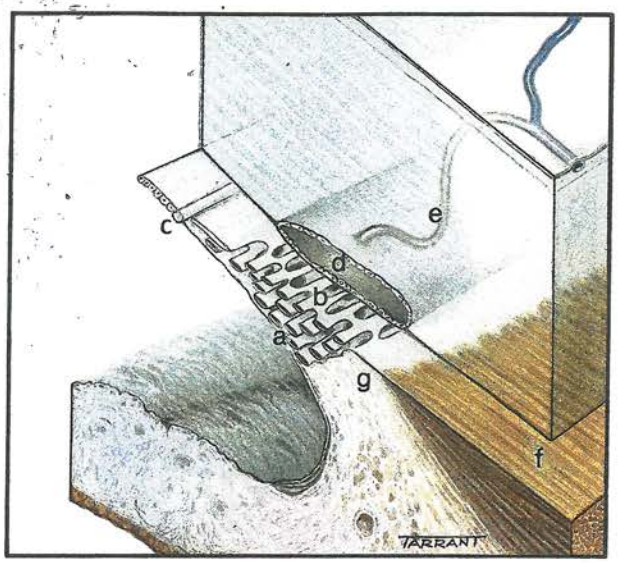

Figure 6.2 Anatomy of the outflow channels. (**a**) Uveal meshwork; (**b**) corneoscleral meshwork; (**c**) Schwalbe line; (**d**) Schlemm canal; (**e**) collector channels; (**f**) longitudinal muscle of the ciliary body; (**g**) scleral spur

Physiology of aqueous outflow

Aqueous flows from the posterior chamber into the anterior chamber through the pupil and is drained by the following routes (Figure 6.3):

1. **Trabecular (conventional) route** (Figure 6.3a) accounts for approximately 90% of aqueous outflow. The aqueous flows through the trabeculum into

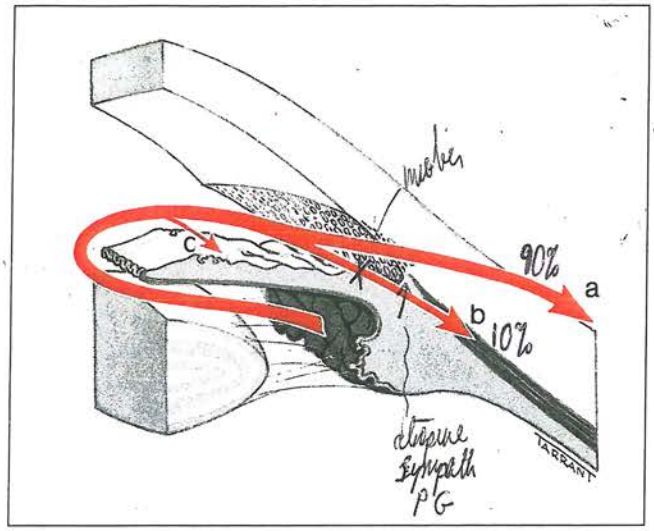

Figure 6.3 Normal outflow of aqueous humour. (**a**) Conventional trabecular route; (**b**) uveoscleral route; (**c**) through the iris

Schlemm canal and is then drained away by the episcleral veins. This is a bulk flow pressure-sensitive route so that increasing the pressure head will increase outflow. Trabecular outflow can be increased by drugs (miotics, sympathomimetics), laser trabeculoplasty and trabeculotomy.

2. **Uveoscleral (unconventional) route** (Figure 6.3**b**) accounts for the remaining 10% of aqueous outflow. The aqueous passes across the ciliary body into the suprachoroidal space and is drained by the venous circulation in the ciliary body, choroid and sclera. Some aqueous also drains via the iris. Uveoscleral outflow is decreased by miotics and increased by atropine, sympathomimetics and prostaglandins. Some aqueous also drains via the iris (Figure 6.3**c**).

Intraocular pressure

1. **Determination of normal IOP** is by the following three factors:
   (a) ***Rate of aqueous secretion***
   (b) ***Resistance encountered in outflow channels***
   (c) ***Level of episcleral venous pressure***

   The rate of aqueous outflow is proportional to the IOP minus the episcleral venous pressure. The relationship between these three factors can be expressed as follows:

   $$Po = (F/C) + Pe$$

   This can also be expressed as $F = C\,(Po - Pe)$ where:

   Po = IOP in mmHg
   F = rate of aqueous outflow (normal 2 µl/min)
   C = facility of aqueous outflow (normal 0.2 µl/min per mmHg)
   Pe = episcleral venous pressure (normal 10 mmHg)

   For example:
   - If episcleral venous pressure is 20 mmHg the IOP will be (2/0.2) + 20 = 30 mmHg.
   - If the facility of outflow is 0.05 the IOP will be (2/0.05) + 10 = 50 mmHg.

2. **The distribution of IOP** within the general population has a range of 11 mmHg to 21 mmHg (mean 16 ± 2.5). Although there is no absolute cutoff point, 21 mmHg is considered as the upper limit of normal and levels above this are viewed with suspicion. However, in some patients glaucomatous damage occurs with IOPs less than 21 mmHg (normal-tension glaucoma) whilst others may remain unscathed with IOPs up to 30 mmHg (ocular hypertension). Although the actual level of IOP is important in the development of glaucomatous damage, other factors also play a part. The level of IOP is inherited so that first-degree relatives of patients with primary open-angle glaucoma have higher pressures.

3. **Fluctuation of normal IOP.** Normal IOP varies with the time of day, heart beat, blood pressure level and respiration. The pattern of diurnal curves of IOP varies in the normal and glaucomatous eye, with a tendency to be higher in the morning and lower in the afternoon and evening. The mean range of diurnal IOP fluctuations in normal eyes is 5 mmHg, and is higher in patients with primary open-angle glaucoma and ocular hypertension. In patients with normal-tension glaucoma the fluctuations are the same as in normals. It is therefore apparent that a single normal reading, particularly if taken during late afternoon, may be misleading and it may be necessary to take several readings at different times of day (phasing). In clinical practice phasing during the morning may be sufficient because 80% of patients will peak between 8 and 12 a.m. The following are the main indications for phasing:
   (a) Ocular hypertension to obtain baseline IOP levels.
   (b) Progressive glaucomatous damage but IOP within the normal range.
   (c) Suspicious optic discs but apparently normal IOPs.

Classification of the glaucomas

The glaucomas are a group of potentially blinding ocular conditions. Because the pathophysiology, clinical presentation and treatment of the different types of glaucoma are so varied, there is no single definition that adequately encompasses all forms. Understanding this concept helps to explain, for example, why one patient with 'glaucoma'

may have no symptoms whilst another experiences sudden pain and redness. In the broadest terms, glaucoma involves a study of the following:

1. **Intraocular pressure.**
2. **Optic nerve head damage.**
3. **Visual field loss.**
4. **Drainage angle.**

The two main types of glaucoma are: (a) ***congenital*** or ***developmental*** and (b) ***acquired***. Further subclassification into open-angle and angle-closure types is based on the mechanism by which aqueous outflow is impaired. The glaucoma may also be primary or secondary depending on the presence or absence of associated factors contributing to the pressure rise. In primary glaucomas the elevation of IOP is not associated with any other ocular disorder whereas in secondary glaucomas a recognizable ocular or non-ocular disorder alters aqueous outflow which, in turn, results in elevation of IOP. Secondary glaucomas may be acquired or developmental, and of the open-angle or angle-closure types.

SECONDARY OPEN-ANGLE GLAUCOMAS

According to the point at which aqueous outflow is obstructed, secondary open-angle glaucomas are subdivided into the following three types:

1. **Pre-trabecular glaucoma**, in which aqueous outflow is obstructed by a membrane covering the trabeculum (Figure 6.4**a**). The membrane may consist of the following:
   (a) Fibrovascular tissue (e.g. neovascular glaucoma).
   (b) Endothelial cells (e.g. iridocorneal endothelial syndrome).
   (c) Epithelial cells (e.g. epithelial ingrowth).
2. **Trabecular glaucoma**, in which the obstruction occurs as a result of 'clogging up' of the meshwork by one of the following:
   (a) Pigment particles (e.g. pigmentary glaucoma, Figure 6.4**b**).
   (b) Red blood cells (e.g. red cell glaucoma).
   (c) Haemolysed red cells (e.g. ghost cell glaucoma).

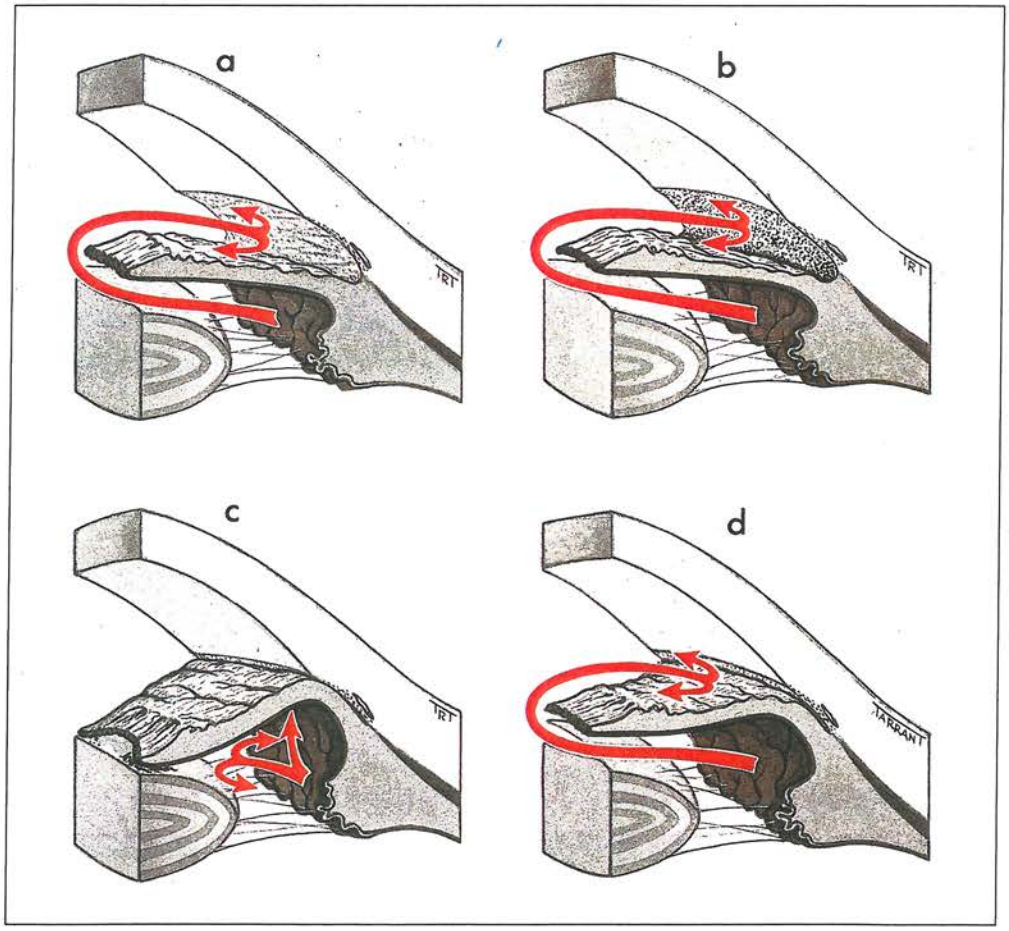

Figure 6.4 Mechanism of aqueous obstruction in secondary glaucomas. (**a**) Pre-trabecular obstruction by a membrane covering the trabeculum; (**b**) trabecular obstruction by pigment granules; (**c**) secondary angle closure caused by pupil block; (**d**) secondary angle closure not associated with pupil block

(d) Macrophages (e.g. phacolytic glaucoma).
(e) Proteins (e.g. acute anterior uveitis).
(f) Pseudoexfoliative material (e.g. pseudoexfoliation glaucoma).

In trabecular glaucomas the trabecular fibres themselves may also be altered by oedema (e.g. herpes zoster iritis) or scarring (e.g. post-traumatic angle recession glaucoma).

3. **Post-trabecular glaucoma**, in which the trabeculum itself is normal but aqueous outflow is impaired as a result of elevated episcleral venous pressure in the following conditions:
   (a) Carotid–cavernous fistulae and dural shunts.
   (b) Sturge–Weber syndrome.
   (c) Obstruction of the superior vena cava.

SECONDARY ANGLE-CLOSURE GLAUCOMAS

In secondary angle-closure glaucoma aqueous outflow is impaired by apposition between the peripheral iris and the trabeculum by either posterior or anterior forces as follows:

1. **Posterior forces** push the peripheral iris against the trabeculum (e.g. iris bombé due to seclusio pupillae, Figure 6.4**c**).
2. **Anterior forces** which pull the iris over the trabeculum by contraction of inflammatory membranes (Figure 6.4**d**) or fibrovascular membranes (e.g. late neovascular glaucoma).

TONOMETRY

Goldmann applanation tonometry

GENERAL PRINCIPLES

Applanation tonometry measures the force applied per unit area. It is based on the Imbert–Fick principle which states that for an ideal, dry, thin-walled sphere, the pressure inside the sphere (P) equals the force necessary to flatten its surface (F) divided by the area of flattening (A) (i.e. $P = F/A$). The IOP is proportional to the pressure applied to the radius or curvature of the globe (in practice the cornea) and the thickness of the globe (i.e. the thickness of the cornea and sclera, which are variable). The human eye is, however, not an ideal sphere and the cornea resists flattening. Capillary attraction of the tear meniscus also tends to pull the tonometer towards the cornea. When measurements are made with the Goldmann tonometer, these forces cancel each other out when the flattened area has a diameter of about 3 mm (Figure 6.5). The Goldmann tonometer is a variable force tonometer consisting of a double prism with a diameter of 3.06 mm (Figure 6.6). It is the most popular tonometer used by ophthalmologists and is the most accurate.

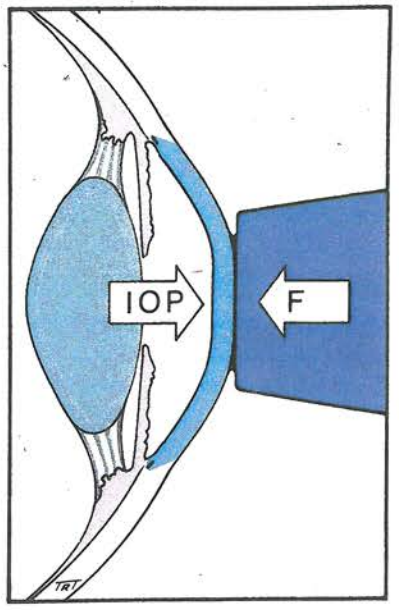

Figure 6.5 Principles of Goldmann applanation tonometry

Figure 6.6 Goldmann applanation tonometer

POTENTIAL ERRORS

1. **Inappropriate fluorescein pattern** resulting from excessive fluorescein will make the semicircles too thick and the radius too small (Figure 6.7**a**), whereas insufficient fluorescein will make the semicircles too thin and the radius too large (Figure 6.7**b**). The correct end-point is when the inner edges of the two

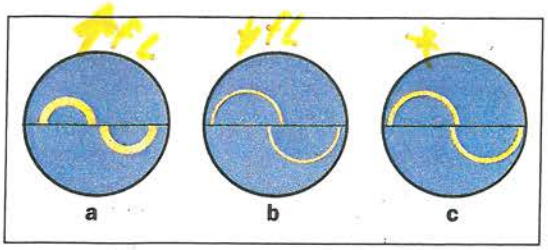

Figure 6.7 Fluorescein-stained semicircles seen during tonometry (*see text*)

semicircles are of the appropriate thickness and just touch (Figure 6.7c).

2. **External pressure on the globe** (Figure 6.8) will result in an artificially high reading.
3. **Incorrect calibration** can result in an incorrect reading. It is therefore important to check the calibration at regular intervals.
4. **Corneal pathology** such as gross oedema or distortion will result in inaccurate readings.

Figure 6.8 Squeezing of the eyelids during tonometery will result in an inaccurate reading

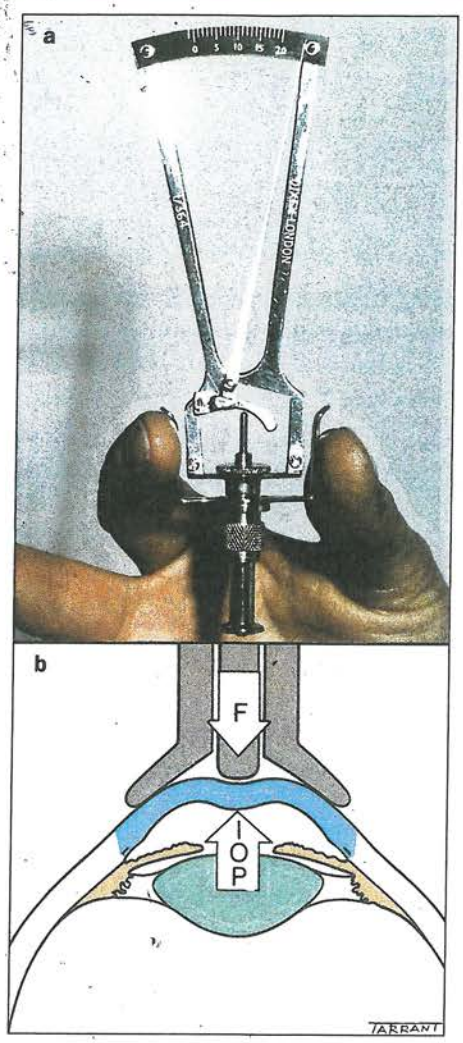

Figure 6.9 **a**: Schiötz tonometer; **b**: principles of indentation tonometry

Other tonometers

1. **The Schiötz** relies on the principle of indentation tonometry in which a plunger with a pre-set weight indents the cornea (Figure 6.9). The amount of indentation is measured on a scale and then the reading is converted into millimetres of mercury by the use of special tables. The tonometer is cheap, easy to use and does not require a slitlamp, but is now seldom used.
2. **The Perkins** is a hand-held applanation tonometer which uses a Goldmann prism adapted to a small light source. It is small, does not require a slitlamp and can therefore be used to measure the IOP in bedbound or anaesthetized patients (Figure 6.10). It does, however, require considerable practice before reliable readings can be obtained.
3. **The air-puff** (Figure 6.11) is a non-contact tonometer which uses the Goldmann applanation principle but, instead of using a prism, the central part of the cornea is flattened by a jet of air. The time required to sufficiently flatten the cornea relates directly to the level of IOP. The instrument is easy to use and does not require a topical anaesthetic. It is therefore particularly useful for screening by non-ophthalmologists. Its main disadvantage is that it is accurate only within the low-to-middle range. The jet of air can surprise the patient both with its apparent force and noise.
4. **The Pulsair 2000 (Keeler)** (Figure 6.12) is a hand-held non-contact tonometer with an automatic alignment activation device which reduces user error. The instrument can be used with the patient in the

Figure 6.10 Perkins hand-held applanation tonometer

Figure 6.11 Air-puff tonometer

Figure 6.12 Pulsair (Keeler) tonometer

upright and supine positions and it does not make a noise. It provides clinically useful measurements comparable with the Goldmann tonometer although with use there is a tendency to a long-term drift in accuracy so that regular re-calibration is mandatory.

5. **The Tono-Pen** is a hand-held, self-contained, battery powered, miniaturized portable tonometer (Figure 6.13). The instrument correlates favourably with the Goldmann although it slightly overestimates a low IOP and underestimates a high IOP. Its main advantage is that it can take measurements in an eye with a distorted or oedematous cornea, as well as through a bandage contact lens.

Figure 6.13 Tono-Pen

GONIOSCOPY

Introduction

PURPOSES

1. **Diagnostic** – to identify abnormal angle structures and to estimate the width of the chamber angle. This is particularly important in the management of eyes with narrow angles.
2. **Surgical** – to visualize the angle during procedures such as laser trabeculoplasty and goniotomy.

OPTICAL PRINCIPLES

The angle of the anterior chamber cannot be visualized directly through an intact cornea because light emitted from angle structures undergoes total internal reflection. A goniolens eliminates total internal reflection by replacing the cornea–air interface by a new tear film-goniolens interface (Figure 6.14).

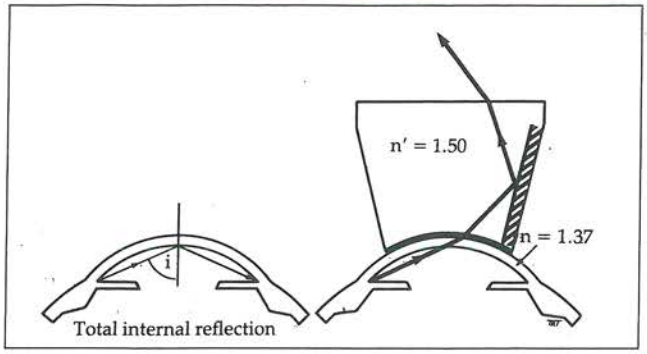

Figure 6.14 Optical principles of gonioscopy: n = refractive index; i = angle of incidence

1. **Indirect goniolenses** provide a mirror image of the opposite angle and can be used only in conjunction with a slitlamp for diagnostic purposes.
2. **Direct goniolenses** provide a direct view of the angle and can be used for both diagnostic and surgical purposes. They do not require a slitlamp and are used with the patient in the supine position.

Goniolenses

INDIRECT GONIOLENSES

1. **The Goldmann three-mirror goniolens** (*see* Figure 9.11) has a contact surface diameter of approximately 12 mm. It is relatively easy to master and gives an excellent view of the angle structures. It also stabilizes the globe and is therefore suitable for argon laser trabeculoplasty. Because the curvature of the contact surface of the lens is steeper than that of the cornea a viscous coupling substance which has the same refractive index as the cornea and which bridges the gap between the cornea and the goniolens is required. Modifications of the Goldmann lens with only one mirror (Figure 6.15) and anti-reflective coating have been designed for laser trabeculoplasty which enable a wider circumference of the angle to be viewed.
2. **The Zeiss**, and the similar Posner, are four-mirror goniolenses which are held by a handle (Figure 6.16). The contact surface of the lens has a diameter of 9 mm and because its curvature is flatter than that of the cornea a coupling substance is not required. Tears provide adequate contact material and lubrication for the lens. This permits a quicker and more comfortable examination of the angle and does not interfere with subsequent examinations of the eye. Once mastered it is easy and quick to use. The four mirrors enable the entire extent of the angle to be visualized with minimal rotation and is very useful for indentation gonioscopy (*see below*) but because it does not stabilize the globe it cannot be used for laser trabeculoplasty.

Figure 6.15 Single mirror goniolens

Figure 6.16 Zeiss four-mirror goniolens

DIRECT GONIOLENSES

1. **The Koeppe** is a dome-shaped diagnostic goniolens which comes in several sizes (Figure 6.17). It is easy to use and provides a panoramic view of the angle. It is therefore particularly useful for simultaneous comparison of one portion of the angle with another. It cannot be used in conjunction with a slitlamp and only with a hand-held microscope. This does not provide the same clarity, illumination and variable powers as with slit-lamp goniolenses.
2. **The Swan–Jacob** is a surgical goniolens which is held on the cornea by a handle (Figure 6.18).



Figure 6.17 Koeppe goniolenses



Figure 6.18 Swan–Jacob surgical goniolens

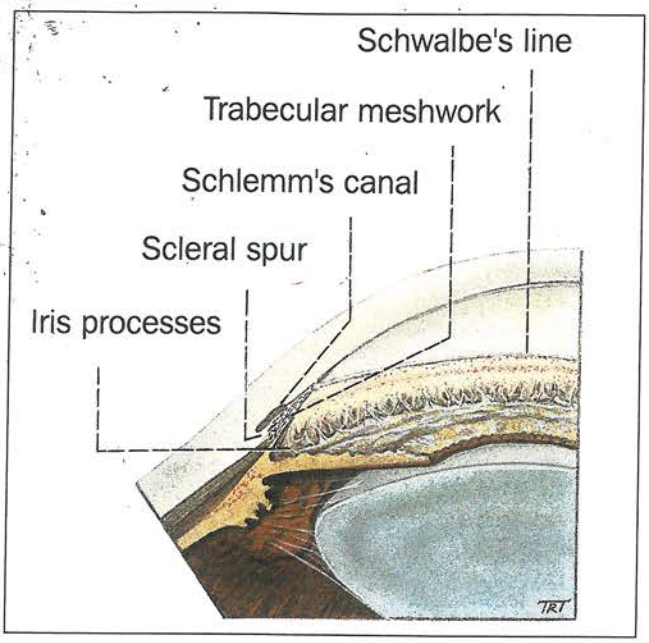

Figure 6.19 Anatomy of angle structures

Interpretation of gonioscopic findings

IDENTIFICATION OF ANGLE STRUCTURES (Figure 6.19)

1. **Schwalbe line** is the most anterior structure, appearing as an opaque line. Anatomically it represents the peripheral termination of Descemet membrane and the anterior limit of the trabeculum.
2. **The corneal wedge** is useful in locating an inconspicuous Schwalbe line as follows: using a narrow slit beam, two linear reflections can be seen, one from the external surface of the cornea and its junction with the sclera, the other from the internal surface of the cornea. The two reflections meet at the apex of the corneal wedge which coincides with Schwalbe line. When performing laser trabeculoplasty a pigmented Schwalbe line should not be confused with the posterior pigmented trabeculum.
3. **The trabeculum** extends from Schwalbe line to the scleral spur and has an average width of 600 μm. Gonioscopically, it has a ground-glass appearance as well as appearing to have depth. The anterior non-functional part lies adjacent to Schwalbe line and has a whitish colour. The posterior functional pigmented part lies adjacent to the scleral spur and has a greyish-blue translucent appearance. Trabecular pigmentation is very rare prior to puberty. In ageing eyes it involves the posterior trabeculum to a variable extent and is most marked inferiorly (Figure 6.20). Pathological trabecular hyperpigmentation is caused by excessive shedding of pigment from the posterior layer of the iris. It may be associated with the following:
   (a) Blunt ocular trauma.
   (b) Anterior uveitis.
   (c) Following acute angle-closure glaucoma.
   (d) Pseudoexfoliation syndrome.
   (e) Pigment dispersion syndrome.
   (f) Diabetes (after cataract surgery).
   (g) Naevus of Ota.

Figure 6.20 Wide open angle with trabecular hyperpigmentation

4. **Schlemm canal** can occasionally be identified in eyes without trabecular pigmentation as a slightly darker line deep to the posterior trabeculum. Blood can sometimes be seen in Schlemm canal if the goniolens compresses the episcleral veins so that the episcleral venous pressure exceeds the IOP. Pathological causes of raised episcleral venous pressure which may be associated with blood in Schlemm canal include:
   (a) Carotid–cavernous fistula and dural shunt.
   (b) Sturge–Weber syndrome.
   (c) Obstruction of the superior vena cava.
5. **The scleral spur** is the most anterior projection of the sclera and the site of attachment of the longitudinal muscle of the ciliary body. Gonioscopically, the scleral spur is situated just posterior to the trabeculum and appears as a narrow, dense, often shiny, whitish band. It is the most important landmark because it has a relatively consistent appearance in different eyes.
6. **The ciliary body** stands out just behind the scleral spur as a pink to dull-brown to slate-grey band. Its width depends on the position of iris insertion and it tends to be narrower in hypermetropic eyes and wider in myopic eyes. The angle recess represents the dipping of the iris as it inserts into the ciliary body.
7. **Iris processes** are small extensions of the anterior surface of the iris which are inserted at the level of the scleral spur and which cover the ciliary body in varying degrees. They are present in about one-third of normal eyes and are most prominent during childhood and in brown eyes. With increasing age they tend to wither and lose their continuity. Iris processes should not be confused with peripheral anterior synechiae which are broader and represent adhesions between the iris and angle structures.
8. **Blood vessels** can often be observed in normal eyes because they run in a radial pattern at the base of the angle recess. Pathological blood vessels, which run randomly in various directions, occur in:
   (a) Neovascular glaucoma.
   (b) Fuchs uveitis syndrome.
   (c) Chronic anterior uveitis.

GRADING OF ANGLE WIDTH

The grading of angle width is an essential part of the assessment of glaucomatous or potentially glaucomatous eyes. Its main aims are to evaluate the functional status of the angle, its degree of closure and the risk of future closure. The following features should be noted and described in the superior and inferior halves of the angle bearing in mind that most angles are narrowest superiorly.

(a) ***The shape and contour of the peripheral iris.***
(b) ***The deepest structure that can be visualized.***
(c) ***The distribution and severity of trabecular pigmentation.***
(d) ***The presence of peripheral anterior synechiae.***

The system of angle grading which is used almost universally today was introduced by Shaffer and records the angle in degrees of arc subtended by the inner surface of the trabecular meshwork and anterior surface of the iris about one-third of the distance from its periphery. An estimation of the angle width is achieved by observing the amount of separation between two imaginary tangent lines constructed to the inner surface of the trabeculum and the anterior iris surface, respectively. In practice, the examiner grades the angle according to the visibility of the various angle structures. The Shaffer grading system (Figure 6.21) provides a method of comparing the widths of different chamber angles. The system assigns a numerical grade (4–0) to each angle with associated anatomical description, the angle width in degrees and implied clinical interpretation.

1. **Grade 4** (35–45°) is the widest angle characteristic of myopia and aphakia in which the ciliary body can be visualized with ease (*see* Figure 6.20); it is incapable of closure.
2. **Grade 3** (25–35°) is an open angle in which at least the scleral spur can be identified; it is also incapable of closure.
3. **Grade 2** (20°) is a moderately narrow angle in which only the trabeculum can be identified; angle closure is possible but unlikely.
4. **Grade 1** (10°) is a very narrow angle in which only Schwalbe line, and perhaps also the top of the trabeculum, can be identified; angle closure is not inevitable but the risk is high.
5. **Slit angle** is one in which there is no obvious iridocorneal contact but no angle structures can be identified; this angle has the greatest danger of imminent closure.
6. **Grade 0** (0°) is a closed angle due to iridocorneal contact and is recognized by the inability to identify the apex of the corneal wedge (Figure 6.22, **right**). *Indentation gonioscopy* using a Zeiss lens is necessary to differentiate 'appositional' from 'synechial' angle closure as follows:

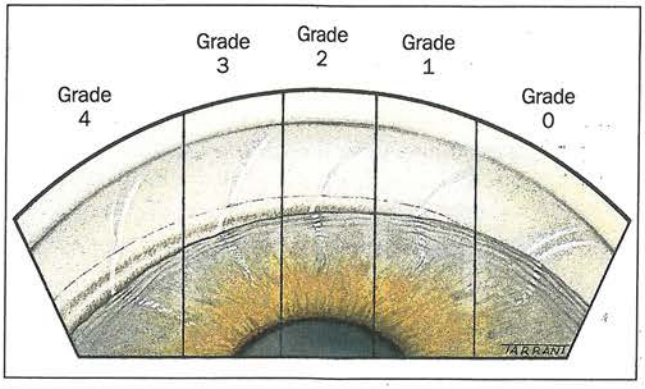

Figure 6.21 Shaffer grading system

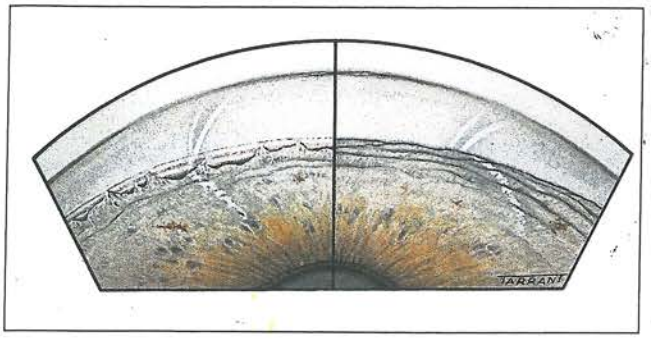

Figure 6.22 Indentation gonioscopy. **Right:** appearance of the angle before indentation showing complete closure and inability to visualize the apex of the corneal wedge; **left:** during indentation part of the angle is forced open but some permanent peripheral synechiae remain

(a) Press the lens posteriorly against the cornea. This will force aqueous into the peripheral part of the anterior chamber and force the peripheral iris posteriorly where it is not supported by the lens.
(b) If the angle is closed by mere apposition between the iris and cornea (appositional closure), the angle will be forced open allowing visualization of the angle recess (Figure 6.22, **left**).
(c) If the angle is closed by adhesions between the peripheral iris and cornea (synechial closure) it will remain closed.

THE OPTIC NERVE HEAD

Applied anatomy

RETINAL NERVE FIBRES

An understanding of the distribution of the 1.2 million axons as they pass across the retina to enter the optic nerve head (optic disc) is the key to the interpretation of visual field loss in relation to optic nerve cupping in glaucoma.

1. **Within the retina** the arrangement is as follows (Figure 6.23):
   (a) Fibres arising from the macula follow a straight course to the optic nerve head forming a spindle-shaped area (papillomacular bundle).
   (b) Fibres arising from the nasal retina also follow a relatively straight course to the optic nerve.
   (c) Fibres arising from the retina temporal to the macula have to follow an arcuate path around the papillomacular bundle to reach the optic nerve head. They do not cross the horizontal raphe that extends from the foveola to the temporal retinal periphery and forms the boundary between the superior and inferior halves of the retina. It should be remembered that *the arcuate fibres reaching the superotemporal and inferotemporal aspects of the optic nerve head are the most vulnerable to glaucomatous damage* and the fibres in the papillomacular bundle are the most resistant.

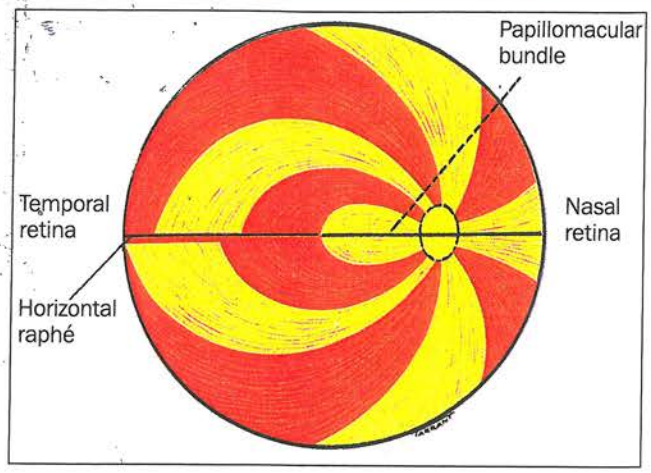

Figure 6.23 Anatomy of retinal nerve fibres

2. **Within the optic nerve head** the retinal fibres are arranged as follows (Figure 6.24):
   (a) Fibres arising from the peripheral part of the fundus lie deep within the retinal nerve fibre layer (i.e. nearer the pigment epithelium) but they occupy the most peripheral (*superficial*) portion of the optic nerve.
   (b) Fibres arising near to the optic nerve lie superficially within the nerve fibre layer (i.e. nearer the vitreous) but they occupy the central (*deep*) portion of the optic nerve.

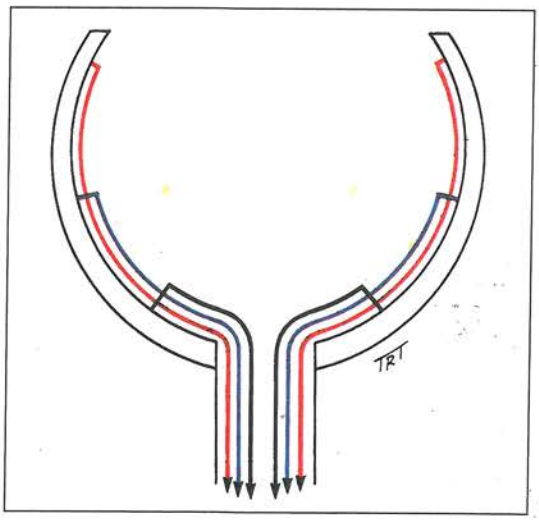

Figure 6.24 Relative positions of retinal neve fibres. **Red:** peripheral; **blue:** equatorial; **black:** central

THE OPTIC NERVE HEAD

1. The **three layers** of the optic nerve head are the following:
   (a) ***The superficial*** layer which is supported by astrocytes and is readily visible with the ophthalmoscope (**a** in Figure 6.25A).
   (b) ***The prelaminar*** layer consisting of retinal nerve fibres which have angled posteriorly from the plane of the retina, is visible only within the central cup (**b** in Figure 6.25A).
   (c) ***The laminar*** layer consisting of the lamina cribrosa and the nerve fibre bundles running through it (**c** in Figure 6.25A).

   The superficial retinal nerve fibre layer is supplied by the central retinal artery and the other two layers are supplied by the short posterior ciliary arteries (circle of Zinn).
2. **The scleral canal** is a hole in the sclera through which the 1.2 million nerve fibres leave the eye. It is usually oval in its vertical axis and has an average vertical diameter of 1.75 mm. The diameter of the scleral canal is related to the size of the optic disc and the globe itself so that eyes with small canals have small optic discs (e.g. hypermetropia) and those with large canals have large discs (e.g. myopia). Variations in the scleral entry of the optic nerve give rise to anomalous congenital optic disc appearances, particularly tilted discs.
3. **The lamina cribrosa** consists of a series of plates of collagenous connective tissue which stretch across the scleral canal. It is perforated by 200–400 openings (pores) containing bundles of retinal nerve fibres. The largest pores are arranged in a vertical hourglass distribution at the superior and inferior poles. The superficial openings of the pores appear as grey dots deep within the optic cup. The large pores have thin connective tissue supports and contain large nerve fibres which are most vulnerable to glaucomatous damage. In glaucomatous eyes the size and shape of the pores are related to the severity of damage. If the damage is slight the pores are small and round, in moderately damaged eyes they are oval, and if the damage is severe they are slit-like.
4. **The optic cup** is a three-dimensional pale depression in the centre of the optic nerve head which is not occupied by neural disc tissue. The pale colour of the cup results from exposure of the lamina cribrosa and loss of glial tissue. The size of the cup is related to the diameter of the disc so that a small disc will have a small cup because the nerve fibres are crowded as they leave the eye. A large disc will have a larger cup because the retinal nerve fibres are less crowded. The following are the three main appearances of the optic cup in normal discs:
   (a) Dimple with a small central cup (Figure 6.26).
   (b) Punched out with a larger and deeper central cup (Figure 6.27).
   (c) Sloping temporal wall (Figure 6.28) .
5. **The neuroretinal rim** is the tissue between the outer edge of the cup and the outer margin of the disc. The

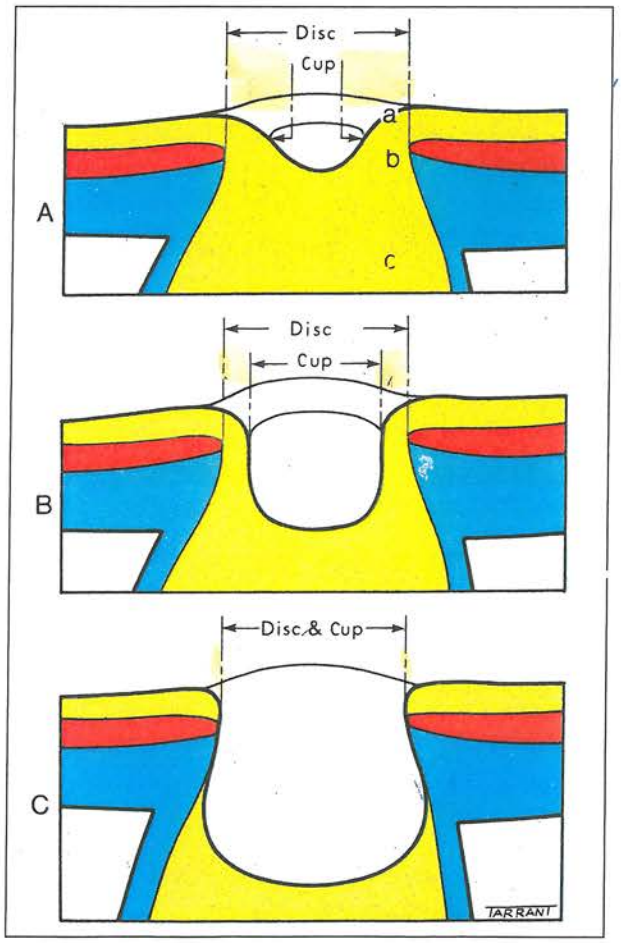

Figure 6.25 Cross-section of the optic nerve head. (**A**) Small physiological cup: **a** = nerve fibre layer, **b** = prelaminar layer, **c** = laminar layer; (**B**) large physiological cup; (**C**) total glaucomatous cupping

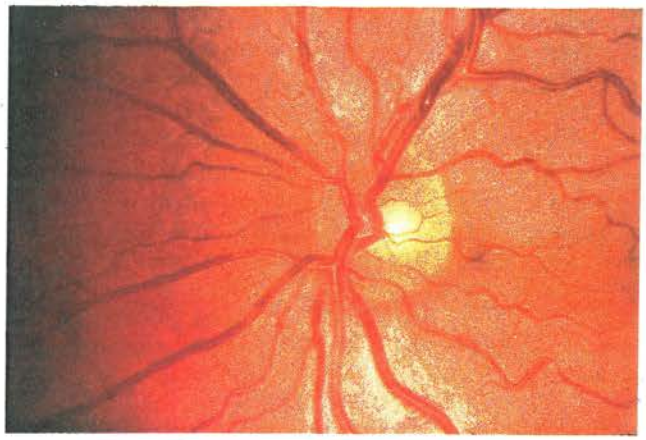

Figure 6.26 Normal disc with small (dimple) cup

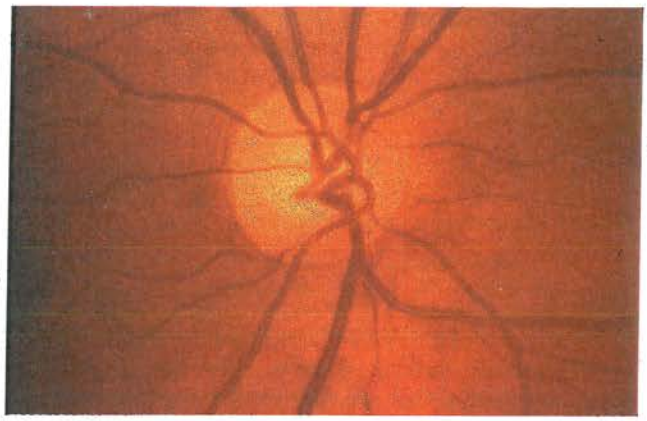

Figure 6.27 Normal disc with a punched out cup

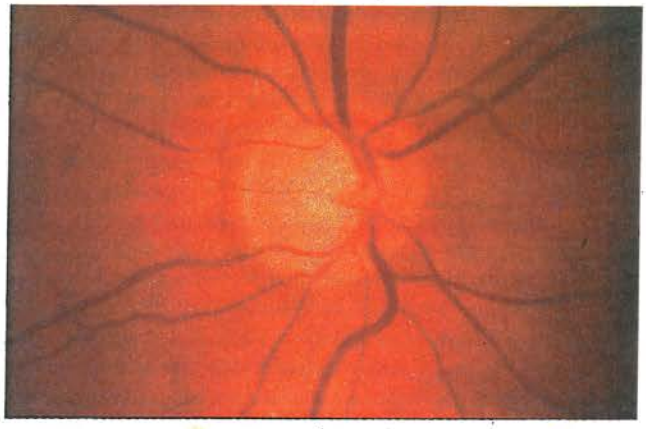

Figure 6.28 Normal disc with a sloping temporal wall in which the area of cupping is larger than the area of pallor

normal healthy rim should have an orange or pink colour and a uniform width. A large physiological cup is due to a mismatch between the size of the scleral canal and the number of traversing nerve fibres which in health remains constant. Pathological cupping is caused by an irreversible decrease in the number of nerve fibres, glial cells and blood vessels (*see* Figure 6.25c).

6. **The retinal blood vessels** enter the disc centrally and then course nasally following the edge of the cup. The central retinal artery is usually nasal to the vein.

Appearance of the optic nerve head

CUP–DISC RATIO

1. **Normal**. The diameter of the cup can be expressed as a fraction of the diameter of the disc both in the vertical and horizontal meridia. This 'cup–disc ratio' is genetically determined and is also dependent on the area of the disc so that the larger the disc the greater the cup–disc ratio. Most normal eyes have a vertical cup–disc ratio of 0.3 or less and only 2% have a ratio greater than 0.7. A ratio greater than 0.7 should therefore be regarded with suspicion although it may not necessarily be pathological (Figure 6.29). Asymmetry between the cup–disc ratios in the two eyes of 0.2 or more should also be regarded with suspicion until glaucoma has been excluded (Figure 6.30).
2. **Glaucomatous expansion** of the optic cup is superimposed upon the amount of physiological cupping present prior to the onset of raised IOP. If an eye with a small cup develops glaucoma, the cup will increase, but during its early stages, its dimensions may still be smaller than that of a large physiological cup. An estimation of the cup size alone is therefore of limited value in the diagnosis of early glaucoma, unless it is found to be increasing. Glaucomatous cups are usually larger than physiological cups, although a large cup is not necessarily pathological. Assessment of the thickness, symmetry and colour

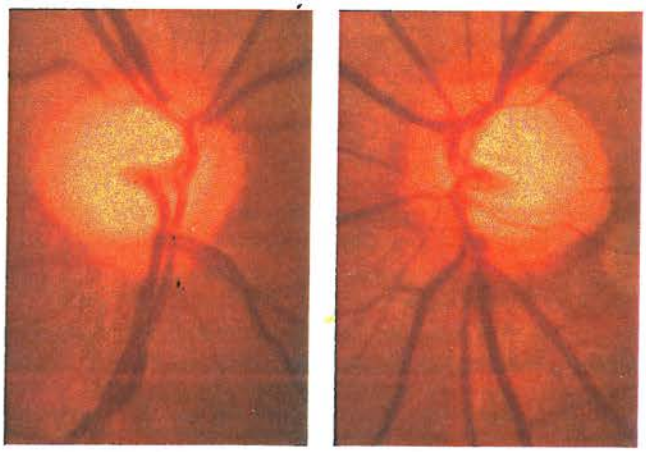

Figure 6.29 Large physiological cups characterized by symmetrical size of cup and intact, neuroretinal rims

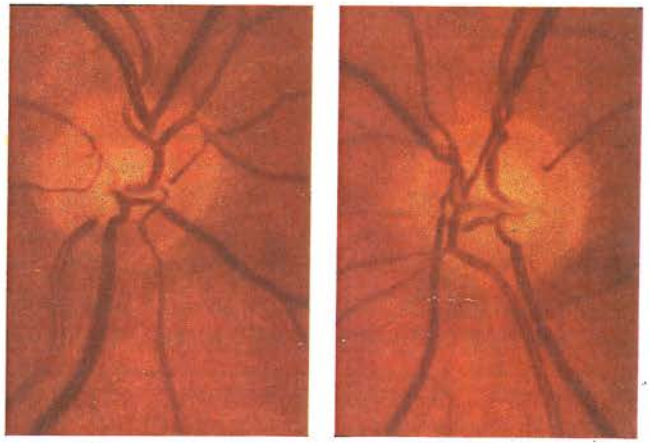

Figure 6.30 Asymmetrical cupping. **Right eye**: cup–disc ratio of 0.3; **left eye**: cup–disc ratio of 0.5

Figure 6.31 Pallor and cupping of normal optic disc with arrows delineating areas of cupping. **Left**: pallor and cupping correspond; **right**: cupping is greater than pallor

of the neuroretinal rim is, however, more important than the characteristics of the cup itself.

PALLOR AND CUPPING

When evaluating a suspicious optic disc it is important not to confuse pallor with cupping (Figure 6.31).

1. **Pallor** is defined as the maximal area of colour contrast, or the area of the optic disc lacking small blood vessels.
2. **Cupping** is best evaluated by observing the bending of the small blood vessels as they cross the disc. In some eyes the areas of cupping and pallor correspond, whereas in others the area of cupping is greater than the area of pallor. In normal eyes the area of cupping increases slightly with age but the area of pallor remains essentially unaltered whereas in glaucomatous eyes both cupping and pallor increase. However, if the area of pallor is greater than cupping, a neurological optic nerve lesion should be suspected.

Glaucomatous damage

Glaucomatous damage is associated with changes involving the retinal nerve fibre layer, the optic nerve head itself and frequently also the parapapillary area. Each will be discussed in turn.

RETINAL NERVE FIBRE CHANGES

Figure 6.32 shows a normal retinal nerve fibre layer visualized with a green filter. In glaucoma subtle retinal nerve fibre layer defects precede the development of detectable optic disc and visual field changes. Retinal nerve fibre drop-out may be either diffuse or localized. Early localized defects are characterized by the presence of slit or wedge-shaped defects in the retinal nerve fibre layer (Figure 6.33). As glaucomatous damage progresses the defects become larger and in end-stage glaucoma there is total atrophy of the nerve fibre layer which is characterized by complete baring of the larger retinal blood vessels. The atrophic area appears darker and mottled because of enhanced visualization of the retinal pigment epithelium (Figure 6.34).

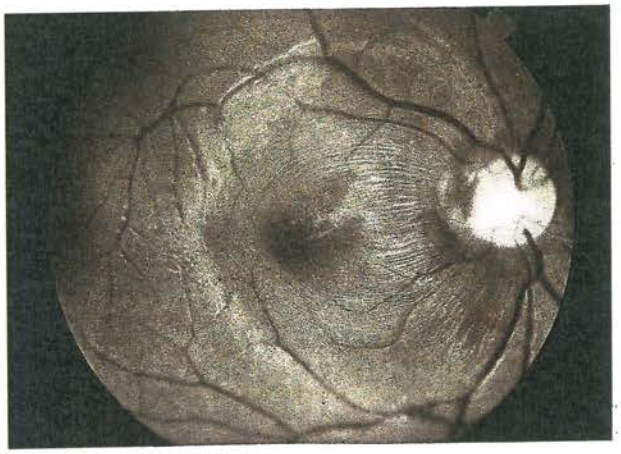

Figure 6.32 Normal retinal nerve fibre layer, best seen with a green filter

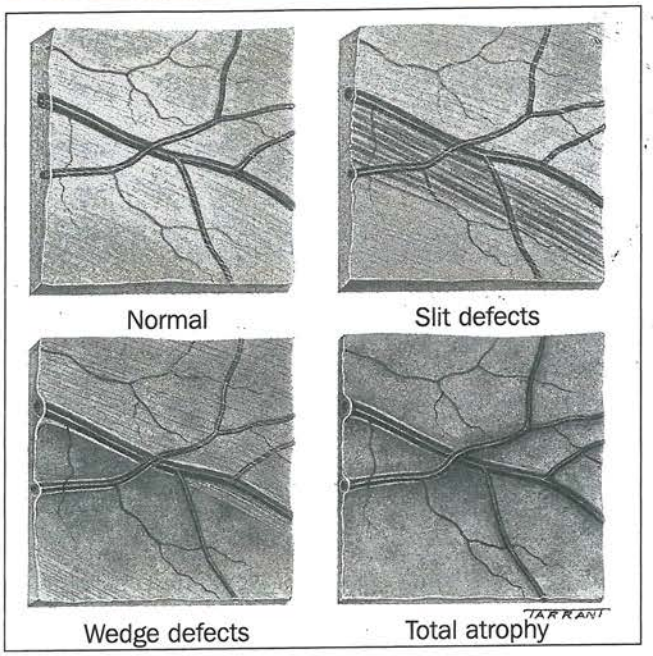

Figure 6.33 Progression of glaucomatous retinal nerve fibre layer damage

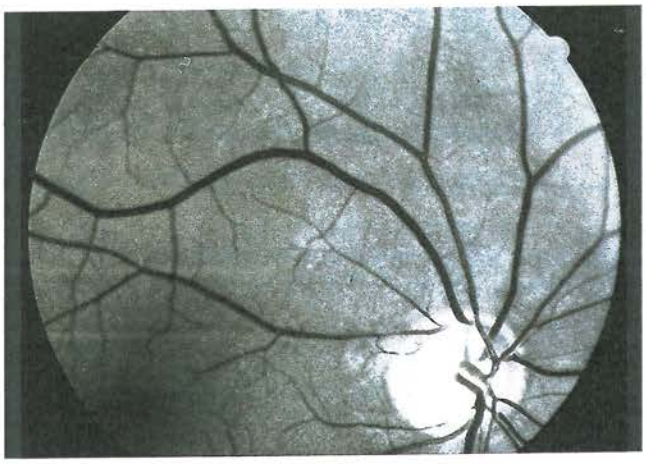

Figure 6.34 Diffuse nerve fibre atrophy in advanced glaucoma. No striations are visible and the retinal blood vessels appear dark and sharply defined

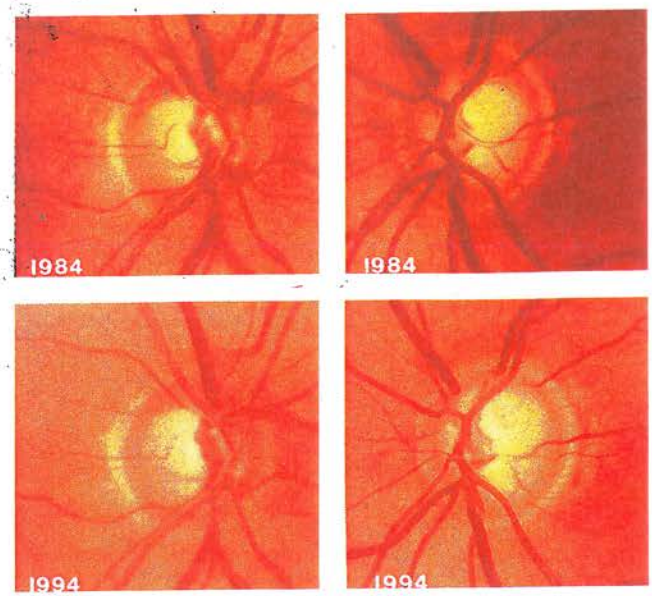

Figure 6.35 Glaucomatous concentric enlargement of the cup over a ten-year period

OPTIC DISC CHANGES

The spectrum of disc damage in glaucoma ranges from highly localized tissue loss with notching of the neuroretinal rim to diffuse concentric enlargement of the cup.

1. **Concentric expansion** is caused by diffuse loss of nerve fibres involving the entire cross-section of the optic nerve head. When this occurs, the excavation simply enlarges concentrically (Figure 6.35). Figure 6.36**a** shows a normal disc with a small physiological cup and a cup–disc ratio of 0.2. Figure 6.36**b** shows the same disc one year after the development of glaucoma. The cup has enlarged concentrically and the cup–disc ratio is now 0.5. This type of glaucomatous cupping may be very difficult to distinguish from a large physiological cup where the cup–disc ratio is still within normal limits. The best way to detect concentric enlargement of the cup is to compare it with a previous record.
2. **Localized expansion** is easier to recognize and is characterized by notching at the superior or more commonly inferior poles of the optic disc (Figure 6.37). In the detection of early cupping, particular attention should therefore be paid to neural tissue loss, especially in the vertical sectors of the cup. In Figure 6.36**c** the cup has expanded infero-temporally but has not yet reached the disc margin. A splinter-shaped haemorrhage on the disc margin, a frequent sign of imminent damage, is also present. In Figure 6.36**d** there is moderate expansion of the cup superiorly and inferiorly. There is also a double angulation of the blood vessels as they dive sharply backwards and then turn along the steep wall of the excavation before angling again onto the floor of the disc ('bayoneting sign').
3. **Advanced changes** progress in the following manner, irrespective of whether the initial damage is diffuse or localized. Figures 6.36**e** shows advanced cupping with total loss of superior and inferior disc tissue. The area of pallor, representing the floor of the cup, is vertically oval. The progressive loss of nasal disc tissue causes a nasal displacement of the central blood vessels emerging from the disc (Figure 6.38). As the damage progresses, the temporal margin of the disc becomes atrophic and finally the nasal rim

Figure 6.36 Progression of glaucomatous optic nerve damage (*see text*)

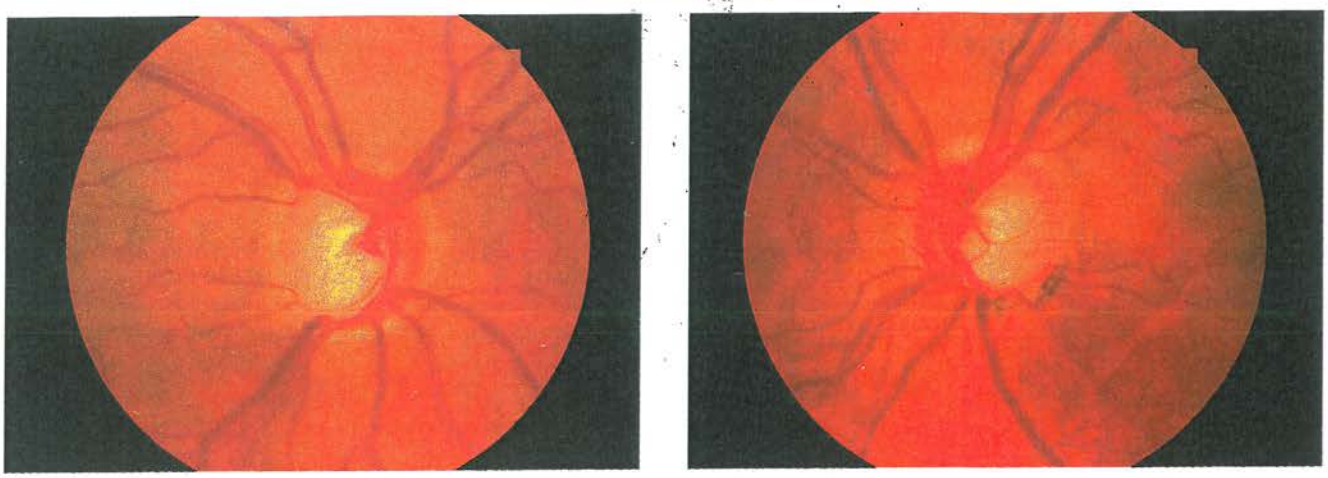

Figure 6.37 Bilateral glaucomatous cupping with inferior notching and 'bayonetting'

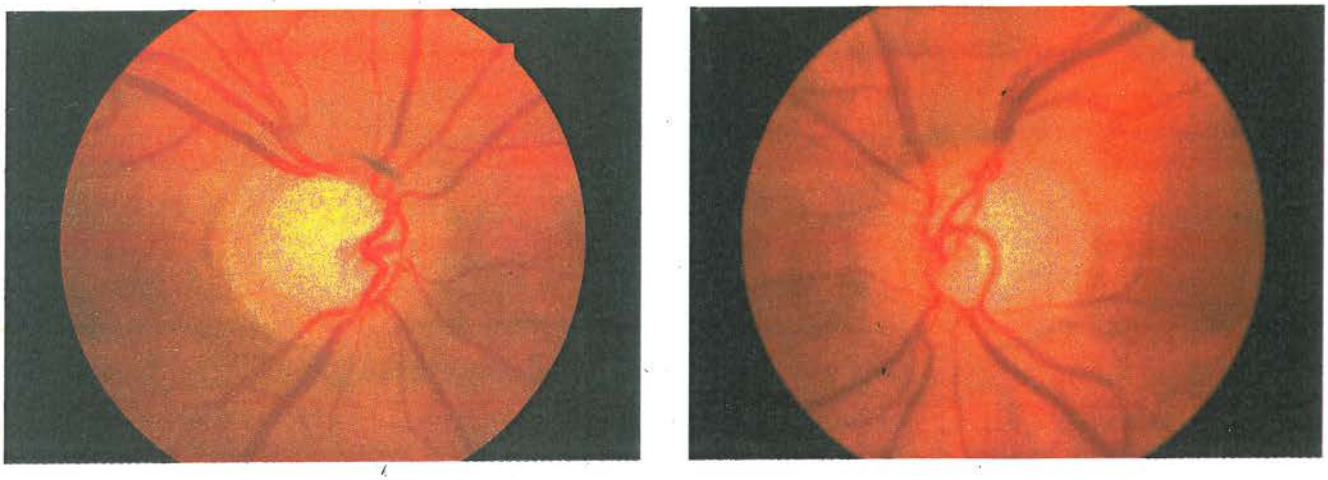

Figure 6.38 Bilateral advanced glaucomatous cupping with nasal displacement of the blood vessels

also disappears. Eventually, all neural disc tissue is destroyed and the optic nerve head appears white and deeply excavated (Figures 6.36f, 6.39).

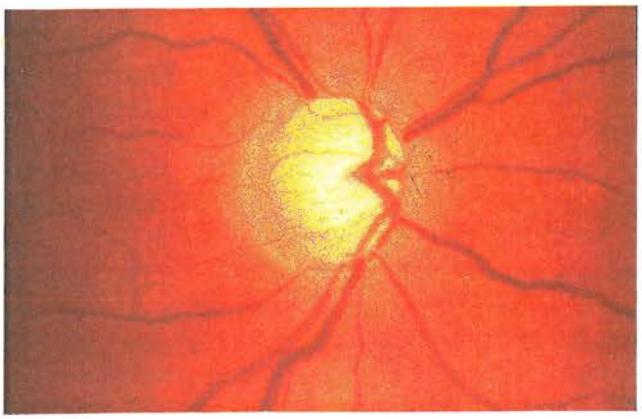

Figure 6.39 End-stage glaucomatous cupping

PARAPAPILLARY CHANGES

Chorioretinal atrophy surrounding the optic nerve head is very common in eyes with high myopia and may also occur in some healthy emmetropic eyes. There is also a correlation between parapapillary atrophy and glaucoma. The changes are classified into the following two zones (Figure 6.40):

1. **A central zone beta**, which borders the peripapillary scleral ring and is characterized by visible sclera and large choroidal blood vessels.
2. **A peripheral zone alpha**, which is characterized by variable irregular hyper- and hypopigmentation of the retinal pigment epithelium.

These parapapillary changes are significantly larger and occur more frequently in glaucomatous than in normal eyes, particularly when there is associated shallow glaucomatous cupping, diffuse retinal nerve fibre loss, a tessel-

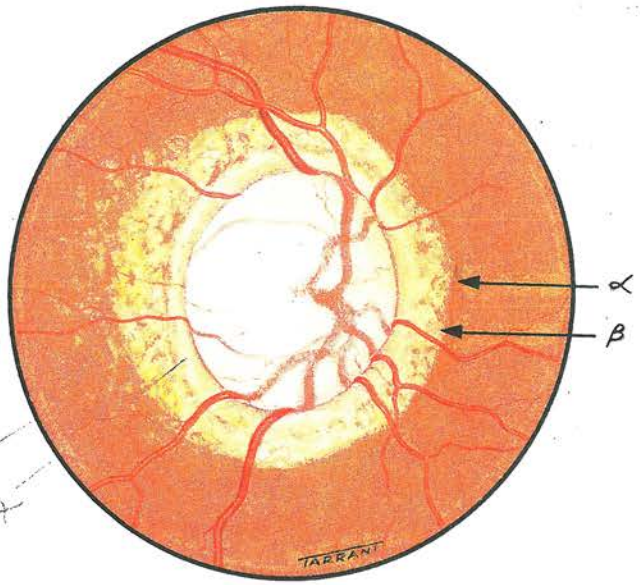

Figure 6.40 Parapapillary changes with a peripheral zone alpha (α) and central zone beta (β) associated with advanced cupping

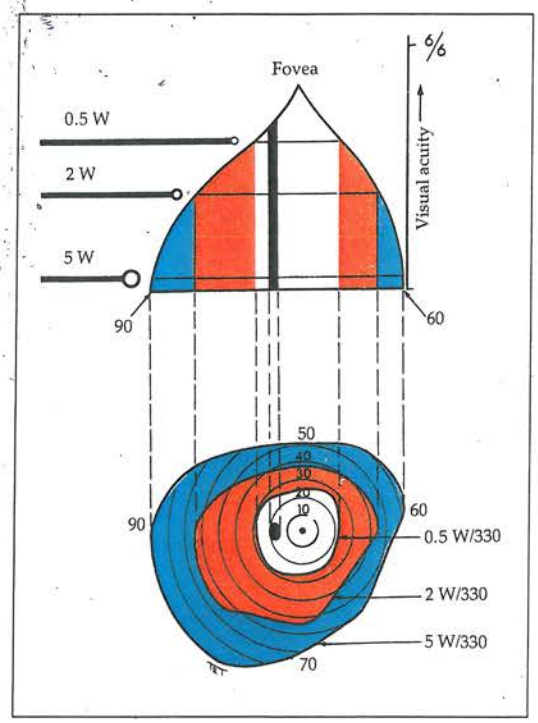

Figure 6.41 Visual field and isopters: 0.5 W/330 = 0.5 mm white target at 0.33 metre; 2 W/330 = 2 mm white target at 0.33 metre; 5 W/330 = 5 mm white target at 0.33 metre

lated fundus and only moderate elevation of IOP. In patients with unilateral glaucoma the changes are more advanced than in the unaffected fellow eye.

PERIMETRY

Definitions

1. **The visual field** is frequently described as being an island of vision surrounded by a sea of darkness. It is not a flat plane but a three-dimensional structure akin to a hill of vision. The outer aspect of the visual field extends approximately 60° nasally, 90° temporally, 50° superiorly and 70° inferiorly (Figure 6.41, **top**). The visual acuity is sharpest at the very top of the hill (i.e. the fovea) and then it declines progressively towards the periphery with the nasal slope being steeper than the temporal. The blind spot is located temporally between 10° and 20°.
2. **An isopter.** As the size and luminance of a target is decreased, the area within which it can be perceived becomes smaller, so that a series of ever-diminishing circles called isopters is formed (Figure 6.41, **bottom**). Isopters therefore resemble the contour lines on a map which enclose an area within which a target of a given size is visible. An erosion of the coastline of the island will therefore cause an indentation of all isopters in the affected area.
3. **A scotoma** is either an absolute or a relative defect in the visual field.
   (a) ***An absolute scotoma*** represents total loss of vision in which even the largest and brightest target cannot be perceived (Figure 6.42**a**).
   (b) ***A relative scotoma*** is an area of partial visual loss within which some targets can be seen and others cannot (Figure 6.42**b**). A scotoma may have sloping edges so that an absolute scotoma is surrounded by a relative scotoma (Figure 6.42**c**).
4. **Luminance** is the intensity or 'brightness' of a light stimulus. An apostilb (asb) is a unit of luminance. A decibel (dB) is a non-specific unit of luminance based on a logarithmic scale (one-tenth of a log unit).
5. **Differential light sensitivity** is the ability of the eye to distinguish a light stimulus from background illumination. The visual field is therefore a three-dimensional representation of differential light sensitivity at different points.
6. **Visible threshold** is the luminance of the stimulus (measured in asb or dB) at which it is perceived 50% of the time when presented statically. The threshold is determined by increasing the intensity of the stimulus by 0.1 log unit steps. The human eye needs about a 10% change in brightness to discern a difference between light stimuli. For example, at a background illumination of 0.1 asb, the eye can detect a light stimulus that is 0.01 asb brighter, while at a background illumination of 1000 asb the eye requires a light that is 100 asb brighter to detect a difference. The threshold sensitivity is highest at the fovea and decreases pro-

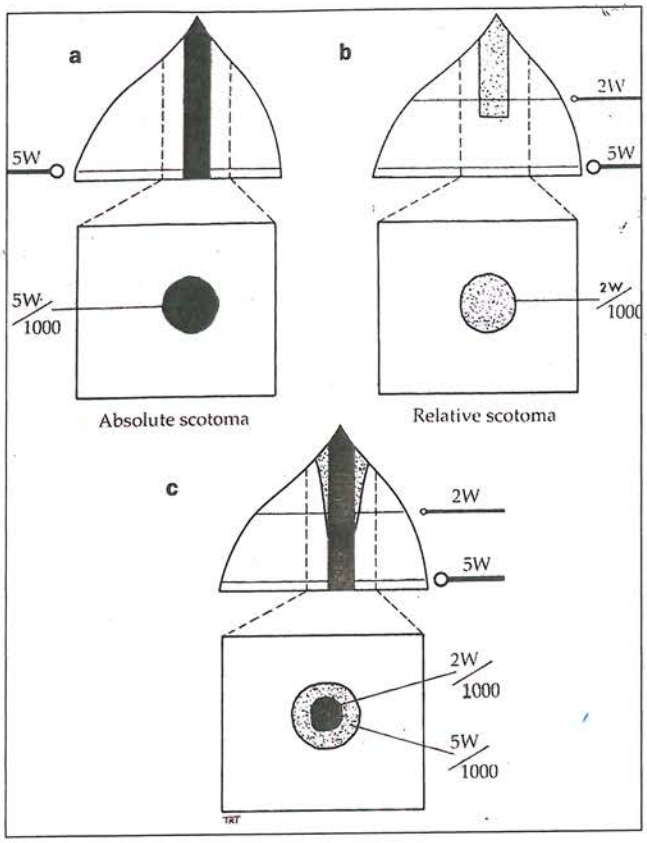

Figure 6.42 (**a**) Absolute scotoma to a 5 mm white target at 1 metre; (**b**) relative scotoma to a 2 mm white target at 1 metre; (**c**) absolute scotoma surrounded by a relative scotoma

gressively towards the periphery. After the age of 20 years the sensitivity decreases by 1 dB per 10 years. For example, at age 20 years the sensitivity at the fovea is 35 dB, at age 30 years it will be 34 dB, and at age 70 years it will be 30 dB.

Perimetric principles

Perimetry is a method of evaluating the visual field. Because of the subjective nature of the patient's responses, efforts have been made to standardize the many aspects of testing in an endeavour to eliminate as many variables as possible. Despite this, when interpreting a visual field defect, it is still very important to take into account the patient's reliability.

1. **Qualitative perimetry** is a method of detecting a visual field defect and is the first screening phase of glaucoma suspects.
2. **Quantitative perimetry** is the next step after a glaucomatous visual field defect has been detected by which its severity in terms of size, shape and depth is determined. Subsequent analysis of the visual field defects is used to determine either stability or progression.
3. **Kinetic perimetry** is a two-dimensional assessment of the boundary of the hill of vision. It involves the presentation of a moving stimulus of known luminance or intensity from a non-seeing area to a seeing area until it has been perceived. The stimulus is moved at a steady speed along a series of meridia and the point of perception is recorded on a chart. By joining these points along different meridians an isopter is plotted for that stimulus intensity. Using different stimulus intensities a contour map of the visual field with several different isopters can be plotted. Kinetic perimetry can be performed by simple confrontation, the tangent screen, Lister perimeter and the Goldmann perimeter.
4. **Static perimetry** is a more difficult concept to perceive but once grasped forms the basis of modern glaucoma assessment. It is a three-dimensional assessment of the height of a pre-determined area of the hill of vision. Static perimetry involves the presentation of stimuli of varying luminance in the same position to obtain a vertical boundary of the visual field. Although it is slower than kinetic perimetry it is much better suited for quantitative testing.

Potential sources of error

1. **Miosis** can give rise to visual field constriction in both visually normal and glaucomatous eyes. Pupils less than 3 mm in diameter should be dilated prior to perimetry.
2. **Lens opacities** have a profound effect on the visual field, particularly when the pupil is also small.
3. **Uncorrected refractive errors** of only 1 D can cause a significant decrease of central visual thresholds.
4. **Ptosis**, even if relatively mild, can result in suppression of the superior visual field.

General principles of automated perimetry

1. **Threshold perimetry** assesses the true hill of vision by plotting the threshold luminance value of the patient in various locations in the visual field and comparing the results with age-matched 'normal' values. Because threshold perimetry performs a quantitative assessment it is the most accurate method of following glaucomatous visual field defects. In areas of a previous defect, a further decrease in the threshold of 5 dB or more is very suggestive and a decrease of 10 dB is usually indicative of further glaucomatous damage.
2. **Suprathreshold perimetry** assesses the hill of vision at a level above which the patient should see the stimulus. First stimuli are presented at luminance levels above normal threshold values (suprathreshold) in

various locations in the visual field. Targets which are detected indicate grossly normal visual function, whereas missed targets reflect areas of decreased visual sensitivity. Missed points can be quantified (i.e. threshold measured). Suprathreshold perimetry in glaucoma is usually limited to screening.

3. **Printouts** of a test contain geographic (i.e. grey scale) and numerical results. The latter generally includes the raw data (i.e. dB at each test location), the difference between the patient's results and that expected of a patient of similar age, and summary data (visual field indices). These indices include an assessment of diffuse field loss, localized defects and patient reliability.

Humphrey perimeter

In the Humphrey perimeter (Figure 6.43, **bottom right**) the target luminance is 3150 asb and the bowl luminance is 31.5 asb.

RELIABILITY INDICES

1. **Fixation losses** are detected by presenting stimuli in the blind spot. If the patient responds a fixation loss is recorded. The lower the number of losses the more reliable the test.
2. **False positives** are detected when a stimulus is accompanied by a sound. If the sound alone is presented and the patient responds a false positive is recorded. A high false positive score suggests a 'trigger happy' patient.
3. **False negatives** are detected by presenting a stimulus that is much brighter than threshold at a location where sensitivity has already been recorded. If the patient fails to respond a false negative is recorded. A high false negative score indicates inattention.

DISPLAYS

1. **Numerical** display gives the threshold (dB) for all points checked (Figure 6.43, **top centre**). The figures in brackets are the value of the threshold at the same point checked a second time if threshold at one point is at least 5 dB less sensitive than expected.
2. **Graphic display** (Figure 6.43, **top right**). Since each step of the pattern corresponds to 5 dB change in sensitivity, the boundary between grey tones is approximately analogous to isopters measured every 5 dB. A 5 dB change in brightness is approximately equivalent to a change of one Goldmann stimulus size.
3. **Total deviation**. The upper numerical display shows the difference (dB) between the patient's results and age-matched normals. The lower graphic display shows these differences as grey symbols.



Figure 6.43 Humphrey printouts (*see text*)

4. **Pattern deviation** is similar to the total deviation except that it is adjusted for any generalized depression in the overall field which might be caused by other factors such as lens opacities or miosis.

GLOBAL INDICES

1. **Mean deviation** (MD) (elevation or depression) is a measure of the patient's overall field from normal reference. The lower the p value the greater its significance; p value categories are $p < 10\%$, $p < 5\%$, $p < 1\%$ and $p < 0.5\%$.
2. **Pattern standard deviation** (PSD) indicates the degree to which the patient's visual field departs from the age-matched reference field.
3. **Short-term fluctuation** (SF) is an indication of the consistency of the patient's responses. It is assessed by measuring threshold twice at ten pre-selected points and is calculated on the difference between the first and second measurement.
4. **Corrected pattern standard deviation** (CPSD) measures how much the overall shape of the patient's hill of vision deviates from age-matched normals.

PROGRAMS

Humphrey test results can be printed out in five threshold test formats, three screening test formats or three STATPAC formats. The 88 point screening test, using a three zone strategy, is a good test to use initially as it is fast and less demanding than the full threshold formats. With the three-zone strategy, an absolute defect is indicated with a black square and a relative defect with a cross. Of the full threshold tests the most used programs are the 30–2 and 24–2. The recently introduced FASTPAC program, while considerably faster to perform, is not as accurate as the standard threshold program at measuring retinal sensitivity. The main advantage of the FASTPAC is greater patient acceptabilty and an increased number of patients capable of performing the test because of its shorter duration.

Visual field defects in glaucoma

EARLY DEFECTS

The following, frequently co-existent early defects are seen with automated perimetry:

1. **Arcuate scotomas** that develop between 10° and 20° of fixation in areas that constitute downward or, more commonly, upward extensions from the blind spot (Bjerrum area, Figure 6.44**a**). Initially the defects do not connect with the blind spot itself but, with the passage of time they tend to elongate circumferentially along the distribution of arcuate nerve fibres (Seidel scotoma).
2. **Isolated paracentral** superior or inferior scotomas may also be found in early glaucoma. Although they are frequently absolute when first detected, they may occasionally disappear after normalization of IOP.
3. **A nasal (Roenne) step** (Figures 6.44**b**) and, very rarely, a **temporal wedge**.

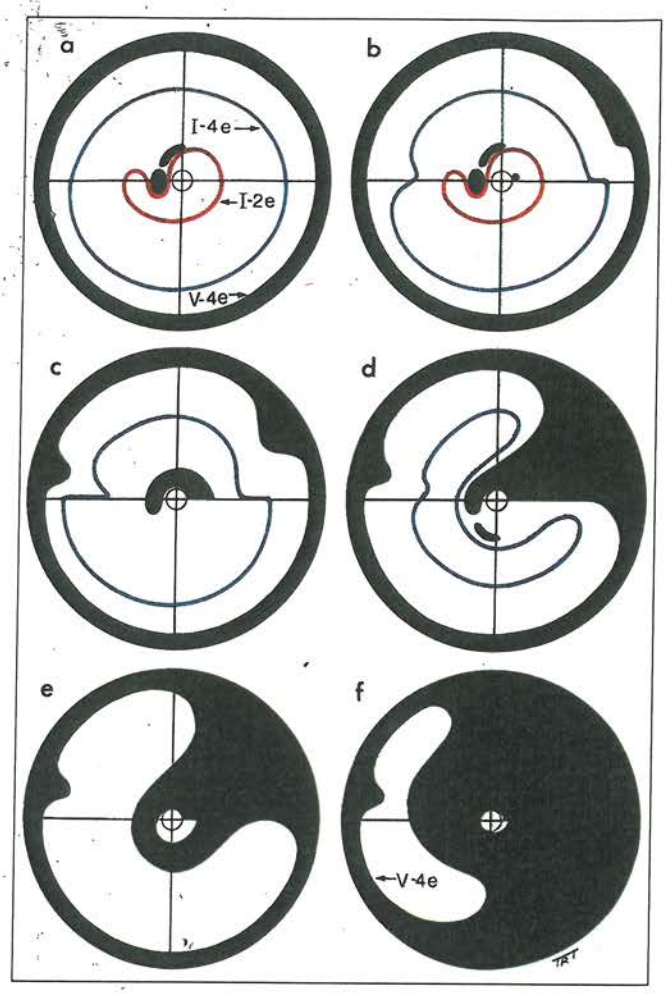

Figure 6.44 Progression of glaucomatous visual field loss (*see text*)

PROGRESSION OF DEFECTS

If glaucomatous damage progresses unabated there is enlargement and deepening of existing scotomas so that those in Bjerrum area coalesce to form an arcuate-shaped defect that arches from the blind spot around fixation reaching to within 5° of fixation nasally (Figure 6.44**c**). Damage to adjacent fibres causes a peripheral breakthrough (Figures 6.44**d**). A ring scotoma develops when arcuate defects in upper and lower halves of the visual field join together (Figure 6.44**e**). The visual field loss gradually

spreads to the periphery and also centrally, eventually leaving only a small island of central vision and an accompanying temporal island (Figure 6.44f). The temporal island is usually extinguished before the central island, although occasionally this sequence is reversed.

OCULAR HYPERTENSION

Introduction

DEFINITION

The term 'ocular hypertension' is used when the IOP is found to be over 21 mmHg on two consecutive visits, in the absence of glaucomatous optic nerve head changes or visual field loss. In population-based studies, the mean IOP is 16 mmHg and two standard deviations on either side of the mean value gives a 'normal' IOP of between 11 and 21 mmHg. The distribution is Gaussian with the curve skewed to the right (Figure 6.45). In the elderly the mean IOP is higher, particularly in women, and the standard deviation greater than in younger individuals. This means that the 'normal' IOP in elderly women may range up to 24 mmHg and not 21 mmHg.

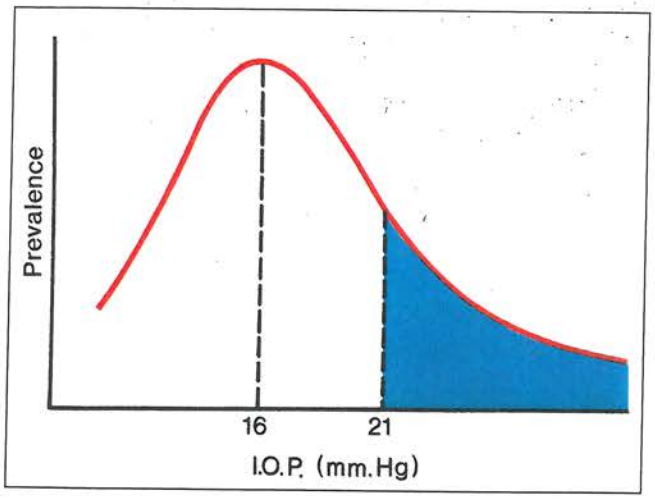

Figure 6.45 Distribution of intraocular pressure in the general population

RISK OF DEVELOPING GLAUCOMA

Although 7–8% of the population over the age of 40 years have IOPs greater than 21 mmHg, only 1% of individuals with ocular hypertension will develop glaucomatous visual field loss each year. The risk of damage increases as the IOP rises. The prevalence of primary open-angle glaucoma (POAG) in relation to screening IOP is shown in Table 6.1.

Table 6.1 Relationship between prevalence of POAG and IOP

IOP (mmHg)	Prevalence of POAG
16–21	1.5%
22–29	8.0%
30 or over	25.0%

There is no infallible way of predicting who will eventually develop glaucoma. Structural changes in the retinal nerve fibre layer and the optic nerve head precede changes in visual function and it can take up to six years before nerve fibre damage becomes manifest as a detectable visual field defect. The risk factors for developing glaucomatous visual field loss in patients with ocular hypertension are as follows:

1. **Nerve fibre layer defects are the most important** (*see* Figure 6.33).
2. **Parapapillary changes** (*see* Figure 6.40).
3. **IOP >30 mmHg at the first visit.**
4. **Vertical cup–disc ratio >0.7** (Figure 6.46).

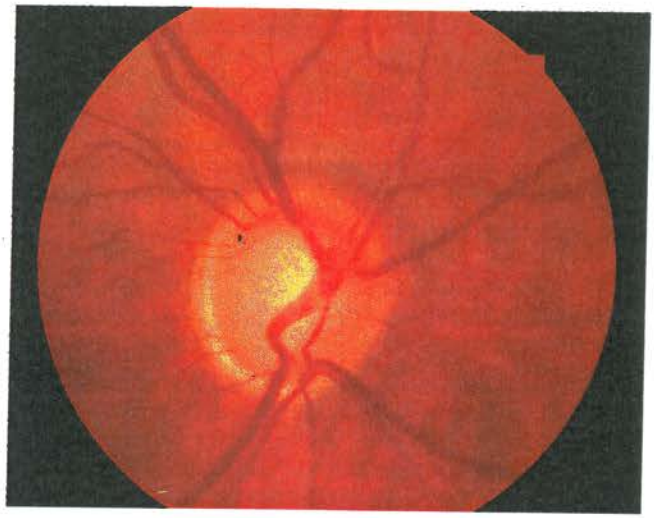

Figure 6.46 Vertical cup–disc ratio is more than 0.7

Management

The decision whether or not to treat patients with ocular hypertension is controversial and it is not possible to formulate a conclusive approach. However, the answer will eventually be provided by prospective randomized studies. It should be remembered that once treatment is instituted, it is usually continued throughout the patient's lifetime and medical therapy may have serious side-effects. For this reason, patients with ocular hypertension who are unlikely to develop damage should not be treated but carefully followed. The following are management guidelines according to the risk of subsequent glaucomatous damage.

1. **High risk factors**
   (a) ***Retinal nerve fibre layer defects.***
   (b) ***Parapapillary changes.***
   (c) ***IOP >30 mmHg.***

When treating this group of patients a change of IOP is more important than a specific level and it is reasonable to aim for a 20% reduction of IOP.

2. **Moderate risk factors**
   (a) ***IOP 24–29 mmHg without nerve fibre layer defects.***
   (b) ***Family history of POAG.***
   (c) ***High myopia.***
   (d) ***Vertical cup–disc ratio >0.7.***

In these patients annual examination of the optic discs and automated visual field testing is appropriate. Treatment is withheld until changes are documented.

3. **Low risk factors**
   IOP 22–23 mmHg.

In these patients an examination every two years is adequate.

PRIMARY OPEN-ANGLE GLAUCOMA

Introduction

DEFINITION

Primary open-angle glaucoma (POAG), also referred to as chronic simple glaucoma, is a generally bilateral although not necessarily a symmetrical disease, characterized by the following:

1. **Adult onset.**
2. **An IOP >21 mmHg at some point in the course of the disease.**
3. **An open angle of normal appearance.**
4. **Glaucomatous optic nerve head damage.**
5. **Visual field loss.**

Despite this definition it should be emphasized that approximately 16% of all patients with otherwise characteristic POAG will have IOPs consistently <22 mmHg and constitute a sub-group referred to as 'normal-tension glaucoma'. POAG is the most prevalent of all glaucomas, affecting approximately 1 in 100 of the general population over the age of 40 years. The condition affects both sexes equally and is responsible for about 12% of all cases of blind registration in the UK and the USA.

RISK FACTORS AND ASSOCIATIONS

1. **Age**: POAG is more common in older individuals and most cases present after the age of 65 years. It is unusual for the diagnosis to be made before the age of 40 years.
2. **Race**: POAG is significantly more common, develops at an earlier age, and is more severe in blacks than in whites.
3. **Family history and inheritance**: POAG is frequently inherited, probably in a multifactorial manner. The responsible gene is thought to show a lack of penetrance and a variation in expressivity in some families. The level of IOP, the facility of outflow and optic disc size are also genetically determined. First-degree relatives of patients with POAG are at increased risk of developing the disease. The risk is increased by a factor of 2 if a parent has the condition and a factor of 4 if a sibling has POAG.
4. **Myopia** is associated with an increased incidence of POAG and myopic eyes are also more susceptible to glaucomatous damage.

CORTICOSTEROID RESPONSIVENESS

The normal population can be divided into three groups on the basis of their IOP response to a six-week course of topical betamethasone.

1. **High responders**, who show a marked elevation of IOP (>30 mmHg).
2. **Moderate responders**, showing a moderate elevation of IOP (22-30 mmHg).
3. **Non-responders**, with virtually no change in IOP.

The incidence of steroid responders in various populations is shown in Table 6.2.

Table 6.2 Incidence of steroid responsiveness (%)

	High	Moderate	Non
General population	5	35	60
Patients with POAG	90	10	0
Siblings of patients with POAG	30	50	20
Offspring of patients with POAG	25	70	5

It has been postulated that the response to topical steroids is determined genetically and the genes that determine steroid responsiveness and POAG are closely related. Topical steroids should therefore be used with caution in patients with POAG as well as in their siblings and offspring. However, no matter if the patient is a high or intermediate steroid responder, the 'strong' steroids (dexamethasone, betamethasone and prednisolone) are equipotent in their ability to raise IOP and the 'weak' steroids (fluorometholone and clobetasone) have a lesser propensity for raising IOP; fluorometholone raises IOP half as

much as betamethasone. It should be noted that systemic steroids are much less likely to cause elevation of IOP.

PATHOGENESIS OF GLAUCOMATOUS DAMAGE

Elevation of IOP in patients with POAG is caused by increased resistance to aqueous outflow in the drainage channels. The development of visual field loss is related to progressive loss of axons in the optic nerve head. Several mechanisms have been postulated to be responsible for this damage, but no single mechanism can adequately explain the great variation in susceptibility to damage and the pattern of damage seen. The two current theories concerning the mechanism of damage are the following:

1. **The ischaemic theory** postulates that compromise of the microvasculature of the axons in the optic nerve head plays a role in the pathogenesis of glaucomatous damage. The possible mechanisms include the following:
   (a) Loss of capillaries.
   (b) Alteration in capillary blood flow.
   (c) Changes that interfere with the delivery of nutrients or removal of metabolic products from the axons.
   (d) Failure of regulation of blood flow.
   (e) Delivery of injurious vasoactive substances to the blood vessels of the optic nerve head.
2. **The direct mechanical theory** suggests that chronically elevated IOP directly damages the retinal nerve fibres as they pass through the lamina cribrosa. Raised IOP induces collapse or alteration of the laminar plates with malalignment of the axonal channels, causing direct impingement on nerve fibres and also results in compromised blood flow and decreased delivery of nutrients to the axons in the optic nerve head.

Clinical features

SYMPTOMS

Patients with POAG are usually asymptomatic until a significant loss of visual field has occurred. This is because the initial visual field loss involves the nasal field which is covered by the field of the other eye. Although the disease is almost always bilateral, progression is often asymmetrical so that patients frequently present with significant visual field loss in one eye and with less advanced disease in the other. Even highly self-analytical individuals may be unaware of large areas of visual field loss although occasionally early defects may be discovered by chance. Rarely, patients with high IOPs may complain of eye ache, headache, and even haloes due to transient corneal epithelial oedema.

SIGNS

1. **Raised IOP:** this objective measurement has remained a stumbling block as well as a great benefit in the diagnosis of POAG. It has been estimated that 2% of the general population over the age of 40 years have IOPs >24 mmHg and 7–8% have IOPs >21 mmHg. However, only approximately 1% have glaucomatous visual field loss. This is further complicated by patients with 'normal' IOP (<22 mmHg) who develop glaucomatous visual field loss and cupping.
2. **Fluctuations in IOP**: approximately 30% of normals show a diurnal variation of IOP of up to 5 mmHg. In POAG this fluctuation is even more marked and occurs in about 90% of cases. For this reason, a single pressure reading of 21 mmHg or less does not necessarily exclude the diagnosis of POAG, nor should a single reading of >21 mmHg do more than arouse suspicion. In order to detect fluctuations of IOP, it may be necessary to measure the IOP at different times during the day (phasing). A discrepancy in the IOP between the two eyes of 5 mmHg or more should be viewed with suspicion on the assumption that, irrespective of the absolute value, the eye with the higher reading is abnormal.
3. **Optic disc changes**: frequently POAG is first diagnosed by finding a suspicious optic disc or asymmetrical discs on routine examination.
4. **Glaucomatous field changes.**
5. **Gonioscopy** shows an open angle without any features to suggest a secondary glaucoma.

Screening

Population screening by simple tonometry alone is not satisfactory because it will label as 'normal' a significant number of cases with other features of POAG such as cupping and visual field loss. In addition, using screening criteria consisting of an IOP >21 mmHg and a vertical cup–disc ratio of >0.4, only 60% of potential POAG patients will be identified. Until more accurate methods of mass screening are available, screening should be selective but thorough and should include visual field examination. Patients with a positive family history of glaucoma in first-degree relatives should be screened from the age of 40 years. Provided the initial assessment is normal, further checks should be at two-yearly intervals until the age of 50 years and then annually thereafter.

Management

The purpose of treatment of POAG is to preserve visual function by controlling IOP and thereby preventing or retarding further optic nerve damage. Regular and careful

follow-up is also important to ensure that any progression is detected early.

BASELINE EVALUATION

The following baseline examination should be performed and clear and concise records kept with which future progress can be compared.

1. **Visual acuity** – with a recording of the spectacle correction.
2. **Slitlamp biomicroscopy**, paying special attention to signs of secondary glaucomas which may masquerade as POAG.
3. **Applanation tonometry** – noting the time of day.
4. **Gonioscopy** should automatically follow applanation tonometry. However, if a goniolens requiring a coupling substance is used, gonioscopy should be delayed until the optic discs and visual fields have been assessed.
5. **Ophthalmoscopy** should be performed and the appearance of the disc documented by drawing and if possible also by photography.
6. **Perimetry** – deciding on the type of perimetry depends on the patient's mobility, age and visual acuity. Lengthy programs in elderly patients with limited visual acuity may not be fruitful but, if possible, a baseline non-sophisticated assessment should be attempted. In patients with significant lens opacities, perimetry should be performed with dilated pupils.

PATIENT INSTRUCTION

A concise explanation should be given to the patient concerning the nature of the disease and an explanatory booklet provided. The patient should be taught how to instil drops and the intervals between medications should be specified. At follow-up visits the patient's technique of instilling drops should be checked. In order to minimize systemic absorption the patient should be instructed either to perform lacrimal sac occlusion or to close the eyes for about three minutes after instillation. The patient should be informed of potential adverse effects and at follow-up visits should be asked if any side effects have been experienced.

GRADING OF SEVERITY OF DAMAGE

The stage of glaucoma can be graded as follows:

1. **Grade 1** (mild damage): early visual field defects and minimal cupping.
2. **Grade 2** (moderate damage): definite arcuate scotoma and thinning of the neuroretinal rim (*see* Figure 6.37).
3. **Grade 3** (severe damage): extensive visual field loss and marked cupping (*see* Figure 6.38).
4. **Grade 4** (end-stage): small residual field remaining and minimal residual neuroretinal rim (**see** Figure 6.39).

TREATMENT GOALS

1. When initiating therapy, one assumes that the pretreatment level of IOP is that which damaged the optic nerve and would subsequently cause additional damage.
2. An IOP level is identified below which further optic nerve damage is considered unlikely to occur. This is the 'target pressure'.
3. The target pressure is identified by taking into account the severity of existing damage, the level of IOP, the rapidity with which damage occurred if that is known, as well as the age and general health of the patient.
4. Therapy should maintain the IOP at or below the target level.
5. The status of the optic nerve and visual fields are monitored for evidence of stability or deterioration. In the event of further damage the target IOP is reset at a lower level.
6. Although the actual safe level of IOP is unknown, progressive damage is uncommon if the IOP is <16 mmHg.

PERIMETRY

Only long-term stability of the visual fields and an unaltered appearance of the optic nerve head are proof that the IOP is at a safe level. If control is good and the appearance of the optic disc stable, yearly perimetry is sufficient. Because pupillary constriction reduces retinal sensitivity and may mimic progressive visual field loss, particularly in older patients with lens opacities, it is necessary to perform perimetry immediately before and soon after the initiation of miotic therapy in order to obtain a baseline. Alternatively, the pupil should be dilated with phenylephrine 2.5% at each subsequent visual field examination.

INITIATION OF MEDICAL THERAPY

Initially only one eye should be treated as a therapeutic trial so that the fellow eye can act as a control. After treatment has been started the patient is seen after two weeks. A fall of IOP of >4 mmHg in the treated eye is considered significant (i.e. caused by the drug as opposed to chance fluctuation) and then treatment to the fellow eye can be commenced. If the response to treatment is satisfactory subsequent assessment is after one month and at 3- to 4-monthly intervals thereafter. Currently, initial treatment is frequently with a topical beta-blocker. Latanoprost, dorzolamide or brimonidine can be used in patients with pulmonary disease. Although miotics are very effective

antiglaucoma agents they are not usually used for initial therapy because of their ocular side effects. If the IOP reduction is not satisfactory, subsequent treatment options include the following:

1. **Increase strength of the drug**: for example, increasing the strength of pilocarpine from 1% to 4% may be beneficial, but increasing timolol from 0.25% to 0.5% is unlikely to reduce the IOP further.
2. **Withdraw the initial drug and substitute another**: for example, stopping a beta-blocker and substituting latanoprost or brimonidine.
3. **Add another drug**: for example, adding pilocarpine or dorzolamide to a beta-blocker is worth considering because of the additive effects of these drugs. When used in combination with a beta-blocker, pilocarpine and dorzolamide may be effective when used only twice daily. When a combination of two drugs is used the patient should be instructed to wait five minutes before instilling the second drug to prevent washout.

CAUSES OF FAILURE OF MEDICAL THERAPY

1. **Inadequate initial goal**: if the IOP runs in the upper part of the statistical normal range, progressive visual field loss is relatively common.
2. **Non-compliance** with medical therapy occurs in at least 25% of patients.
3. **Wide fluctuations** in IOP frequently occur in patients treated medically.

LASER TRABECULOPLASTY

Laser trabeculoplasty is a procedure by which the application of discrete burns to the trabeculum enhances aqueous outflow and lowers IOP. The following are the main indications for this procedure:

1. **Uncontrolled glaucoma** despite 'maximal tolerated medical therapy'. However, it should be emphasized that this rarely includes the strongest miotics or systemic carbonic anhydrase inhibitors. Patients younger than 55 years should be considered for early laser therapy if the IOP is uncontrolled with twice daily medication with beta-blockers and/or dorzolamide because miotics are unlikely to be well tolerated. Laser therapy is also of particular use in elderly patients with uncontrolled glaucoma as it may indefinitely defer the need for trabeculectomy.
2. **As primary therapy** in patients who do not comply or are expected not to comply with medical therapy. Because IOP reduction with laser is seldom greater than 30%, eyes with IOPs >28 mmHg are unlikely to be adequately controlled by laser alone.

TRABECULECTOMY

Progressive damage is less likely to occur after trabeculectomy than with medical therapy because the IOP level is normally significantly lower and fluctuations are less after surgery. The timing of trabeculectomy depends on the amount of visual loss that has occurred, the rapidity of visual deterioration and the patient's life expectancy. The decision is influenced by the individual surgeon's experience as well as by national and international trends. In general, the following are the main indications for surgery:

1. **Failed medical therapy** and **laser trabeculoplasty**.
2. **Lack of suitability for laser therapy** due to the following:
   (a) Poor patient cooperation.
   (b) Inability adequately to visualize the trabeculum because of a narrow angle or corneal opacification.
3. **Eyes with advanced disease** where a very low IOP is required may benefit from early surgery before first undergoing laser therapy.

NORMAL-TENSION GLAUCOMA

Introduction

DEFINITION

The term normal-tension glaucoma (NTG), which is also referred to as low-tension glaucoma, is used to describe a type of POAG which is characterized by the following:

1. A mean IOP equal to or less than 21 mmHg on diurnal testing.
2. Glaucomatous optic disc damage and visual field loss.
3. Open drainage angle on gonioscopy.
4. Absence of secondary causes for glaucomatous optic disc damage.

It should be remembered, however, that the division of POAG into two types (i.e. normal-tension and high-tension) based on an epidemiologically derived normal IOP, is essentially arbitrary and may not have significant clinical value. The prevalence of NTG in individuals over the age of 40 years is 0.2% and the condition accounts for 16% of all cases of POAG.

RISK FACTORS

1. **Age**: NTG tends to occur in the elderly.
2. **Gender**: females are at greater risk by a 2:1 ratio.

3. **Race**: NTG is more common in Japan than in either Europe or North America.

Clinical features

1. **The IOP** is usually in the high teens, but may rarely be in the low teens. In the presence of asymmetrical disease the more damaged disc corresponds to the eye with the higher IOP.
2. **The optic nerve head** is larger in NTG than in POAG. There is no difference in the appearance of either glaucomatous cupping or parapapillary changes although the incidence of splinter haemorrhages at the disc margin is higher in NTG (Figure 6.47).

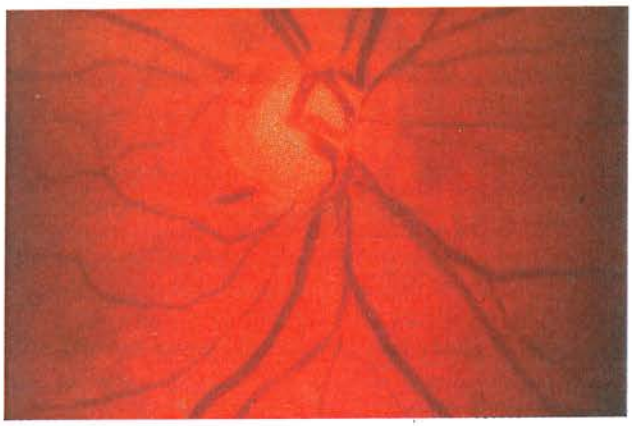

Figure 6.47 Glaucomatous cupping with a splinter haemorrhage at 7 o'clock

3. **Visual field defects** are essentially the same as in POAG although it has been suggested that in NTG they tend to be closer to fixation, deeper, steeper and more localized. In some patients, even without treatment, the visual field changes are non-progressive but because of the more frequent delay in diagnosis, patients with NTG tend to present with more advanced damage than those with POAG.
4. **Other characteristics** which are more common in patients with NTG than in those with POAG are:
   (a) Peripheral vascular spasm on cooling.
   (b) Migraine headaches are said to be more common, although this has not been confirmed in a population-based survey.
   (c) Nocturnal systemic hypotension as well as over-treated systemic hypertension.
   (d) Reduced blood flow velocity in the ophthalmic artery when measured with transcranial Doppler ultrasonography.
   (e) Paraproteinaemia and the presence of serum autoantibodies.

Management

1. **History**: a careful history should be taken to exclude episodes of raised IOP as may occur as a result of ocular trauma, chronic anterior uveitis or administration of topical steroids. A past history of acute blood loss or shock causing infarction of the optic nerve head is also important because it may explain the abnormal appearance of the optic nerve head.
2. **Reduction of IOP** is indicated only in patients with documented progressive visual field loss. The aim is to reduce the IOP by at least 30%. Betaxolol may be the drug of choice because it increases optic nerve blood flow in addition to lowering IOP. If progressive visual field loss occurs despite an IOP in the lower teens, trabeculectomy should be considered in at least one eye.
3. **Systemic calcium-channel blockers** (e.g. nifedipine) may be considered in younger patients and in those with early disease. Ideally, peripheral vasospasm should be confirmed by nailfold capilloscopy before the commencement of treatment. Long-term therapy should be prescribed only if the visual fields remain stable or show improvement after a short-term (2–3 month) therapeutic trial.
4. **Monitoring of systemic blood pressure** for 24 hours. If a significant nocturnal drop is detected, medication for hypertension, especially if taken prior to bedtime, should be avoided. The patient should be allowed to take normally salted food and encouraged to increase physical activity (an afternoon walk may be adequate). The benefit of systemic fludrocortisone to increase blood pressure in normotensive individuals is not proven.

Differential diagnosis

1. **POAG** presenting initially with normal IOP because of a wide diurnal swing of IOP. This can be excluded by phasing (diurnal IOP curve) over an eight-hour period in order to detect a pressure spike of over 21 mmHg.
2. **Congenital optic disc anomalies** such as large optic disc pits (Figure 6.48) or colobomas (Figure 6.49) which may be mistaken for acquired glaucomatous cupping.
3. **Neurological lesions** causing optic nerve or chiasmal compression with visual field defects which may be misinterpreted as being glaucomatous. In these cases neuroradiological investigations should be performed.
4. **Previous ischaemic optic neuropathy**, especially the arteritic form, may give rise to a disc appearance which is very similar to that seen in advanced glaucoma.

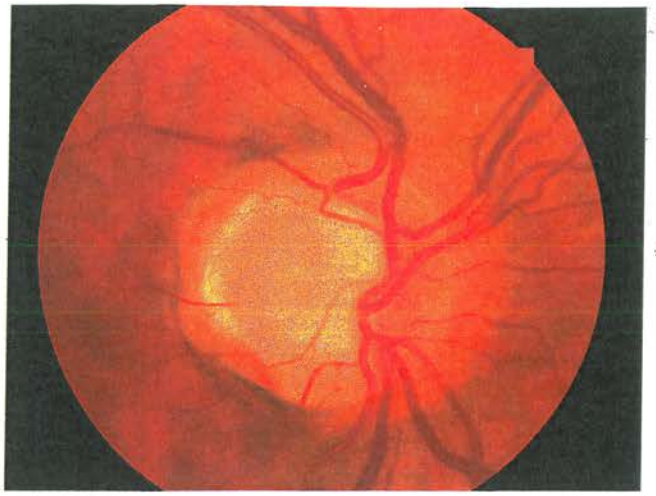

Figure 6.48 Congenital pit of the optic disc which may be mistaken for glaucomatous cupping

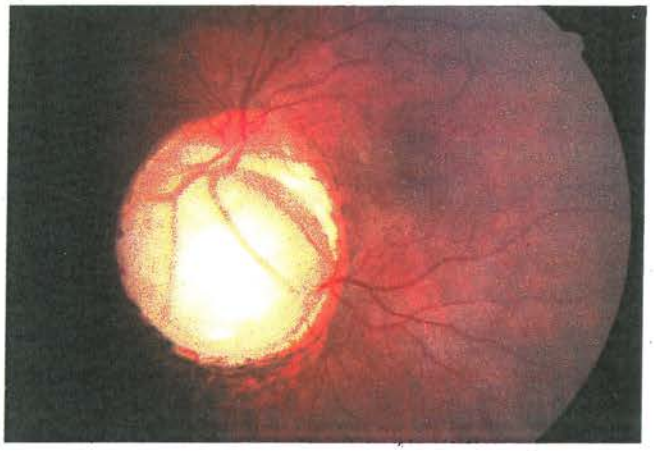

Figure 6.49 Optic disc coloboma which may be mistaken for glaucomatous cupping

PRIMARY ANGLE-CLOSURE GLAUCOMA

Introduction

DEFINITION

Primary angle-closure glaucoma (PACG) is a condition in which elevation of IOP occurs as a result of obstruction of aqueous outflow by partial or complete closure of the angle by the peripheral iris. Unlike POAG, the diagnosis depends to a great extent on examination of the anterior segment and careful gonioscopy. The presence of a normal optic nerve head and absence of visual field loss does not preclude the diagnosis of PACG. The disease occurs in anatomically prediposed eyes and is frequently bilateral, although presentation of the acute form is frequently asymmetrical. Based on the mechanism of angle closure, the two forms of PACG are: pupillary block and the much less common plateau iris syndrome.

RISK FACTORS

1. **Age**: the average age at presentation is about 60 years and the prevalence increases thereafter.
2. **Gender**: females are more commonly affected than males by a ratio of 4:1.
3. **Race**: in whites the condition accounts for about 6% of all glaucomas and it affects approximately 1 in 1000 individuals over the age of 40 years. PACG is more common in South-East Asians, Chinese and Eskimos but uncommon in blacks.
4. **Family history**: because ocular anatomical features are inherited, including anterior segment depth and iris configuration, first-degree relatives are at increased risk.

ANATOMICAL PREDISPOSING FACTORS

1. **Relatively anterior location of the iris–lens diaphragm.**
2. **Shallow anterior chamber.**
3. **Narrow entrance to the chamber angle.**

The proximity of the cornea to the peripheral iris enables angle closure to occur more easily than in a normal eye. The following three interrelated factors are responsible for these characteristics:

(a) ***Lens size.*** The lens is the only ocular structure which continues to increase in size throughout life. Axial growth brings its anterior surface closer to the cornea and equatorial growth slackens the suspensory ligament and allows the iris–lens diaphragm to move anteriorly. Both of these factors cause a very gradual and progressive shallowing of the anterior chamber and a decrease in anterior chamber volume with ageing. Eyes with PACG have shallower anterior chambers (1.8 mm) than normal eyes (2.8 mm), and women have shallower anterior chambers than men.

(b) ***Corneal diameter.*** The depth of the anterior chamber and width of the angle are related to the corneal diameter. Eyes with PACG have corneal diameters 0.25 mm smaller than normal eyes. For this reason eyes with microcornea are at increased risk of angle-closure glaucoma.

(c) ***Axial length.*** In normal eyes the relative position of the lens and the corneal diameter are related to the axial length of the globe. A short eye, which is also frequently hypermetropic, has a small corneal diameter and a relatively anteriorly located lens. For this reason eyes with nanophthalmos are at increased risk of angle-closure glaucoma.

PHYSIOLOGICAL PRECIPITATING FACTORS

The immediate physiological precipitating factors of acute PACG in predisposed eyes are not fully understood. At present the following two theories exist:

1. **The dilator muscle theory** postulates that contraction of the dilator muscle exerts a posterior vector. This increases the amount of apposition between the iris and the anteriorly located lens and enhances the degree of physiological pupil block (Figure 6.50**a**). The simultaneous dilatation of the pupil renders the peripheral iris more flaccid. The relative pupil block causes the pressure in the posterior chamber to increase and the peripheral iris bows anteriorly (iris bombé; Figure 6.50**b**). Eventually the angle becomes obstructed by the peripheral iris and the IOP rises (Figure 6.50**c**).
2. **The sphincter muscle** theory postulates that the sphincter of the pupil is the prime culprit in precipitating angle closure. The pupillary blocking force of the sphincter is greatest when the diameter of the pupil is approximately 4 mm.

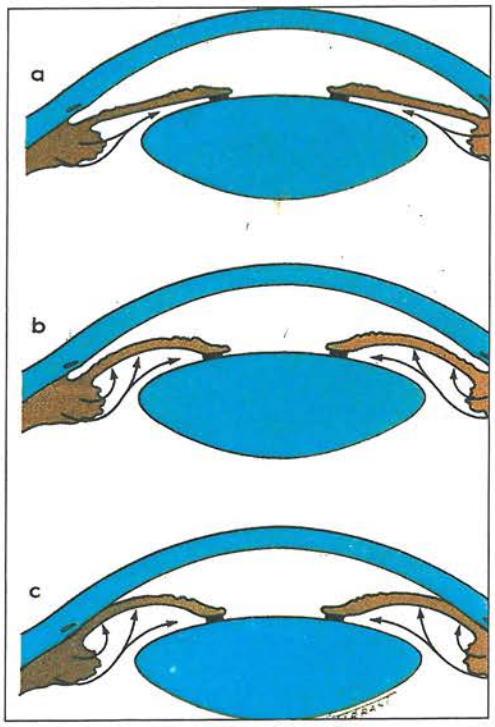

Figure 6.50 Mechanism of angle closure. (**a**) Relative pupil block; (**b**) iris bombé; (**c**) iridotrabecular contact

CLASSIFICATION

Although PACG can be divided into five overlapping stages the condition does not necessarily progress from one stage to the next in an orderly sequence. In practice, a combination of these clinical types is often seen.

1. **Latent.**
2. **Intermittent (subacute).**
3. **Acute: congestive and postcongestive.**
4. **Chronic.**
5. **Absolute.**

The latter is the end-stage of acute congestive PACG in which the eye is completely blind and it will not be discussed further.

Latent angle-closure glaucoma

CLINICAL FEATURES

The asymptomatic phase of PACG is characterized by the following signs:

1. **Slitlamp biomicroscopy** shows the following:
   (a) Shallow anterior chamber which can be demonstrated by shining a light across the eye from the temporal side, demonstrating a crescent of shadow on the nasal side of the anterior chamber ('eclipse' sign, Figure 6.51)
   (b) Convex-shaped iris–lens diaphragm (Figure 6.52).
   (c) Close proximity of the iris to the cornea (Figure 6.53).
2. **Gonioscopy** shows an 'occludable' angle in which the pigmented trabecular meshwork is not visible – Shafer grade 1 (*see* Figure 6.21) without indentation or manipulation in at least three of four quadrants.

TREATMENT

1. If one eye has had acute or intermittent PACG, treatment of the fellow eye is by prophylactic peripheral laser iridotomy because, without treatment, the risk of an acute attack during the next five years is about 50%.

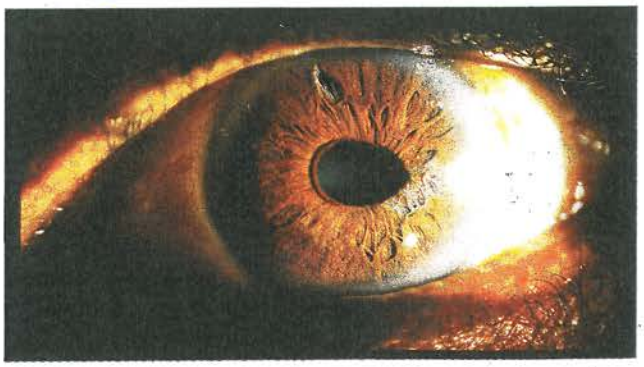

Figure 6.51 'Eclipse' sign which is elicited by directing a light across the anterior chamber from the temporal side and noting a shadow on the nasal side

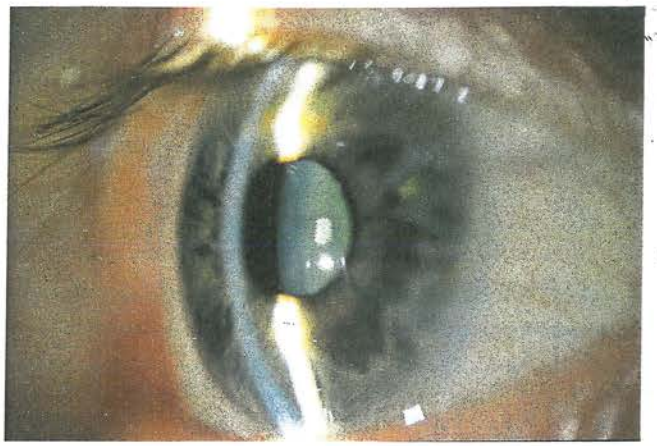

Figure 6.52 Shallow anterior chamber

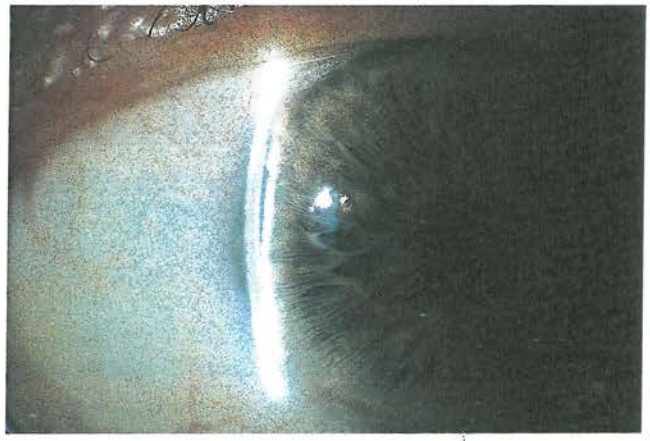

Figure 6.53 Close proximity of iris to the peripheral cornea

2. If both eyes have latent PACG, there is no parameter or provocative test that has enough sensitivity or accuracy to determine which eyes will later develop acute PACG. However, because the risks of laser iridotomy are small, if carefully undertaken, laser treatment should be considered in these cases. Although prophylactic laser iridotomy will prevent an acute attack, 15% of eyes may develop a late rise in IOP. Without treatment an eye with latent PACG may follow one of the following pathways:
   (a) Remain normal.
   (b) Develop acute or intermittent angle closure.
   (c) Develop chronic angle closure without passing through an acute or subacute phase.

Intermittent angle-closure glaucoma

Intermittent (subacute) PACG occurs in a predisposed eye with an occludable angle in association with intermittent pupillary block. A rapid closure of the angle results in a sudden increase in IOP. The pupillary block is then spontaneously broken, the angle opens and the IOP returns to normal levels. The attacks may be precipitated by physiological mydriasis (watching television in a dark room), or by a physiological shallowing of the anterior chamber when the patient assumes a prone or semiprone position (when sewing or reading). Emotional stress may occasionally be a precipitating factor.

CLINICAL FEATURES

The diagnosis is based on a characteristic history of transient blurring of vision associated with haloes around lights due to corneal epithelial oedema (the blue end of the spectrum being nearer the source). There may also be some associated eye ache or frontal headache. The attacks are recurrent and are usually broken after 1–2 hours by physiological miosis (exposure to bright sunlight or sleep). During an attack the eye is usually uncongested and in between attacks it looks perfectly normal although the angle is narrow.

TREATMENT

When the characteristic symptoms are present, treatment is with prophylactic peripheral laser iridotomy. Without treatment some eyes will develop an acute attack and others may develop chronic angle closure.

Acute congestive angle-closure glaucoma

CLINICAL FEATURES

Acute congestive angle closure is caused by a sudden total closure of the angle.

1. **Symptoms** are as follows:
   (a) Rapidly progressive impairment of vision.
   (b) Periocular pain and congestion.
   (c) Nausea and vomiting in severe cases.
   It is important to note the variability of symptoms of acute angle-closure attacks. Some patients, particularly blacks in whom the condition is uncommon, have remarkably little pain and no congestion despite very high IOPs and the only symptom is impairment of vision. In addition, only a few patients will give a history of transient blurring and haloes characteristic of previous intermittent attacks.
2. **Slitlamp biomocroscopy** shows the following:
   (a) 'Ciliary' flush due to injection of the limbal and conjunctival blood vessels (Figure 6.54).
   (b) IOP is severely elevated (50–100 mmHg).
   (c) Corneal oedema with epithelial vesicles (Figure 6.55).
   (d) The anterior chamber is shallow with peripheral iridocorneal contact (Figure 6.56).

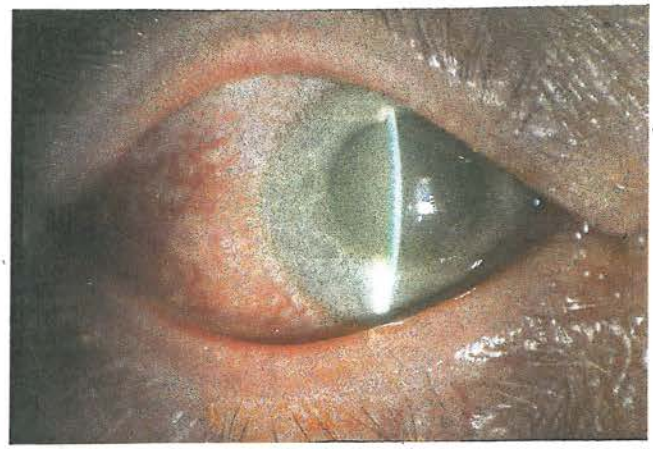

Figure 6.54 Acute angle-closure glaucoma showing ciliary injection, corneal oedema and a dilated pupil

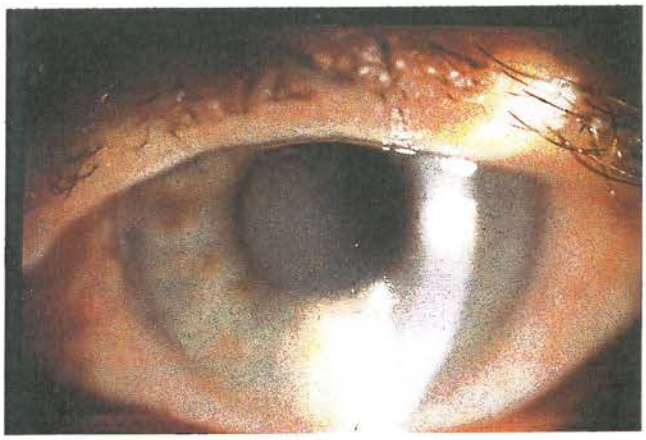

Figure 6.55 Corneal oedema in acute congestive angle-closure glaucoma

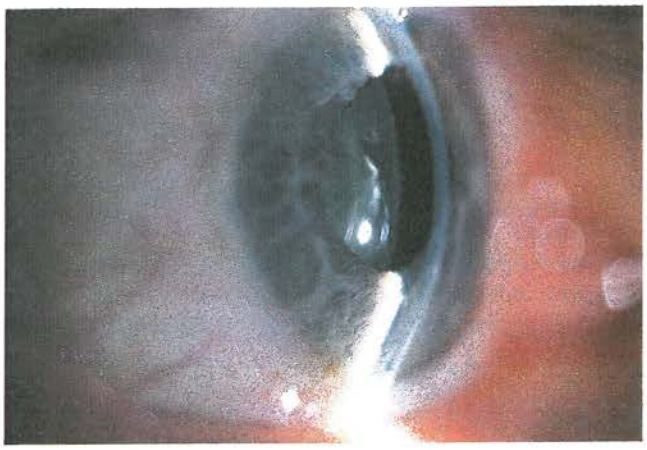

Figure 6.56 Very shallow anterior chamber with peripheral iridocorneal contact

(e) Aqueous flare and cells may be seen once the corneal oedema has resolved.

(f) The pupil is vertically oval and fixed in the semidilated position and is unreactive to both light and accommodation. The iris blood vessels are dilated.

3. **Gonioscopy** shows complete peripheral iridocorneal contact – Shaffer grade 0 (Figure 6.57).
4. **Ophthalmoscopy**, when possible, shows optic disc oedema and hyperaemia.

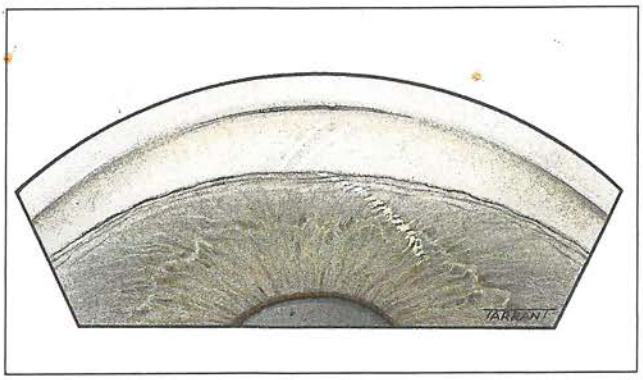

Figure 6.57 Gonioscopy showing complete angle closure

DIFFERENTIAL DIAGNOSIS

1. **Secondary angle closure** by an intumescent (swollen) cataract or a dislocated lens.
2. **Neovascular glaucoma** may occasionally cause a sudden onset of pain and congestion.
3. **Glaucomatocyclitic crisis**.
4. **Other causes of headache** around the eye such as migraine or migrainous neuralgia (cluster headache).

INITIAL MEDICAL THERAPY

1. **Intravenous acetazolamide** 500 mg is given initially followed by oral acetazolamide 250 mg four times daily after the acute attack has been broken. There is no point in giving acetazolamide intramuscularly.
2. **Hyperosmotic agents** are used if the IOP is extremely high and if acetazolamide is ineffective. The dose of oral glycerine is 1–1.5 g/kg of a 50% solution in lemon juice and the dose of intravenous mannitol is 2 g/kg of a 20% solution.
3. **Topical therapy**
   (a) Pilocarpine 2% should be started approximately half to one hour after commencement of treatment when reduction of iris ischaemia and an IOP <40 mmHg allows the pilocarpine to function. There is no place for 'intensive' miotic therapy. The fellow eye is also treated prophylac-

tically with pilocarpine 1% four times daily until a laser iridotomy can be performed.

(b) Beta-blockers twice daily combined with steroids four times daily may also be helpful in lowering the IOP and decongesting the eye.

PERIPHERAL Nd:YAG LASER IRIDOTOMY

1. **The purpose** of peripheral laser iridotomy is to re-establish the communication between the posterior and anterior chambers by making an opening in the peripheral iris. This will be successful only if less than 50% of the angle is closed by permanent peripheral anterior synechiae (synechial closure).
2. **Timing** will vary according to the severity of the attack and the rapidity of corneal clearing. In many cases laser iridotomy may be difficult and dangerous during an acute attack and should not be attempted until the corneal thickening and iris congestion have settled (usually 48 hours). After an explanation has been given, it may be appropriate to perform a prophylactic laser iridotomy on the fellow eye in the interim period. Laser iridotomy is effective in about 75% of eyes with acute angle-closure glaucoma. Unresponsive cases require a trabeculectomy.

Postcongestive angle-closure glaucoma

PATHOGENESIS

Postcongestive angle-closure glaucoma may be seen in the following three clinical settings:

1. **Postsurgical** in which the IOP is normalized by successful peripheral iridotomy or trabeculectomy. It should be pointed out that after peripheral iridotomy the IOP may still be somewhat elevated in some eyes due to the associated trabecular damage despite the fact that 50% or more of the angle is open. These cases will require topical therapy to control the IOP.
2. **Spontaneous angle re-opening** without treatment may occur in a few cases; the management is the same as for intermittent angle closure.
3. **Ciliary body shutdown** in which a temporary decrease in aqueous secretion occurs as a result of ischaemic damage to the secretory ciliary epithelium in the presence of complete angle closure. In these eyes a subsequent recovery of ciliary function may lead to a chronic elevation of IOP with optic disc cupping and visual field loss. It is important to confirm that the angle is open after peripheral iridotomy even if the IOP is normal.

CLINICAL FEATURES

1. **Slitlamp biomicroscopy** may show a combination of the following signs:
   (a) IOP may be normal, subnormal or elevated.
   (b) Folds in Descemet membrane (Figure 6.58), if the IOP has been reduced rapidly.

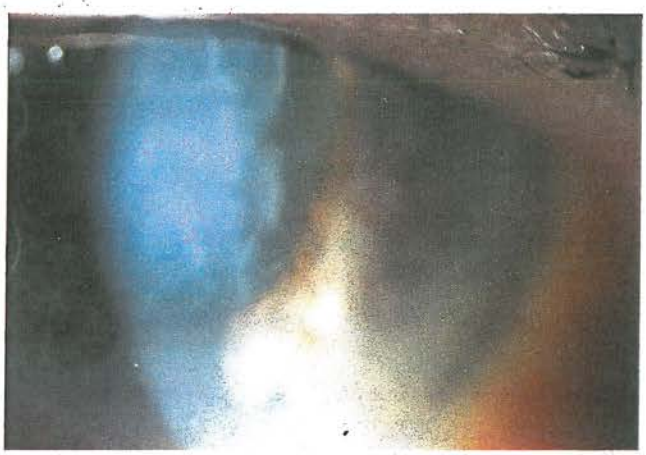

Figure 6.58 Postcongestive angle-closure glaucoma showing folds in Descemet membrane and residual corneal oedema

   (c) Fine pigment granules on the corneal endothelium.
   (d) Stromal iris atrophy with a spiral-like configuration (Figure 6.59) and fine pigment granules on its surface.
   (e) A fixed and semidilated pupil (Figure 6.60) due to a combination of paralysis of the sphincter and posterior synechiae.
   (f) Aqueous flare and cells.
   (g) Glaukomflecken characterized by small, grey–white, anterior subcapsular or capsular lens opacities in the pupillary zone (Figure 6.61) are diagnostic of a previous congestive attack.

Figure 6.59 Postcongestive angle-closure glaucoma showing iris atrophy and a fixed pupil

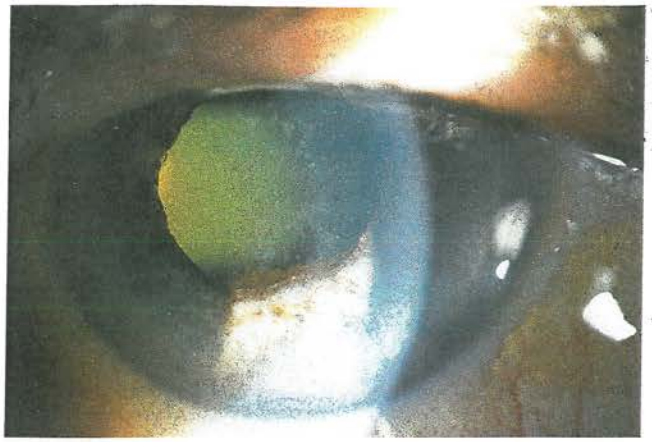

Figure 6.60 Postcongestive angle-closure glaucoma showing a dilated pupil and posterior synechiae

Figure 6.61 Anterior subcapsular lens opacities (glaukomflecken) following acute angle-closure glaucoma

2. **Gonioscopy** shows a narrow angle which may be open or partly closed. If open, trabecular hyperpigmentation may be present. A straight line of pigment may be seen anterior to Schwalbe line at the site of previous iridocorneal contact.
3. **Ophthalmoscopy** may show congestion of the optic disc and choroidal folds if the IOP is very low. In other cases optic atrophy (Figure 6.62) may be present as a result of infarction.

Chronic angle-closure glaucoma

PATHOGENESIS

Chronic angle-closure glaucoma occurs in the following three settings:

1. **Type 1** (creeping) is caused by gradual and progressive synechial angle closure which always starts

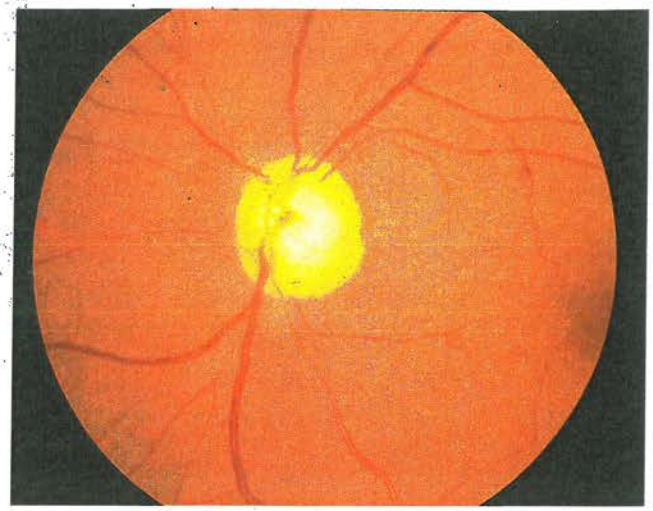

Figure 6.62 Optic atrophy resulting from a severe and prolonged attack of acute angle-closure glaucoma

superiorly and spreads inferiorly (Figure 6.63). It has been postulated that this may be caused by anteriorly situated ciliary processes and many eyes have a plateau iris configuration (*see below*).
2. **Type 2** is caused by synechial angle closure as a result of intermittent (subacute) attacks secondary to pupillary block.
3. **Type 3** (mixed) is caused by a combination of POAG with narrow angles usually associated with the long-term use of miotics.

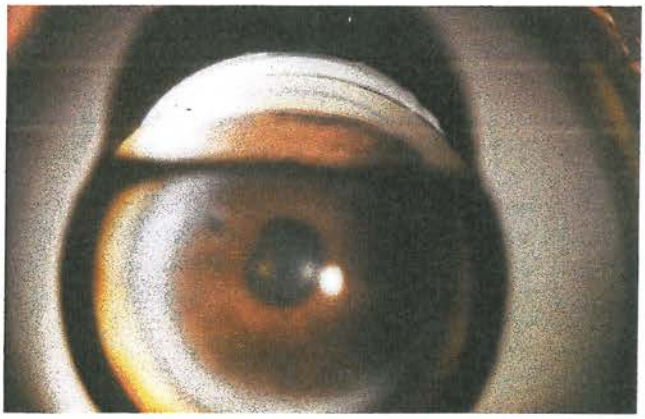

Figure 6.63 'Creeping' angle closure in chronic angle-closure glaucoma

CLINICAL FEATURES

The clinical features are similar to those found in POAG. Gonioscopy shows a variable amount of angle closure, although permanent peripheral anterior synechiae do not usually develop until late. The diagnosis will be missed unless routine gonioscopy is performed on all glaucomatous eyes.

TREATMENT

1. **Type 1** (creeping) is initially treated by laser iridotomy to eliminate any element of pupil block. Any subsequent increase of IOP is then treated medically. If laser iridotomy and medical therapy are unsuccessful, trabeculectomy will be required.
2. **Type 2** will already have had an iridotomy because of intermittent angle closure. In these cases medical therapy should be added as necessary.
3. **Type 3** (mixed) will already be on medical therapy for POAG. A narrow angle will be diagnosed by gonioscopy either when laser trabeculoplasty is considered or when control is becoming more difficult. These cases should be treated by laser iridotomy.

Plateau iris configuration and syndrome

CLINICAL FEATURES

1. **Plateau iris configuration** is characterized by a closed anterior chamber angle in association with a flat iris plane and a deep central anterior chamber. An anterior position of the ciliary processes results in an abnormal configuration of the peripheral iris. Although this mechanism of angle closure is rare in whites, it is not uncommon in South-East Asians.
2. **Plateau iris syndrome** describes acute angle closure which occurs with pupillary dilatation despite a patent iridotomy. The syndrome tends to occur at a younger age than angle closure with pupillary block. When the pupil dilates, the peripheral iris becomes 'bunched up' and occludes the trabeculum. All the features of acute congestive angle closure are present except that the axial anterior chamber depth is normal and the iris plane is flat and not convex.

TREATMENT

Treatment is with pilocarpine 1% drops after performing a laser peripheral iridotomy. It may also be possible to flatten the 'hump' in the peripheral iris with argon laser (gonioplasty).

PSEUDOEXFOLIATION SYNDROME AND GLAUCOMA

Pseudoexfoliation syndrome

INTRODUCTION

The pseudoexfoliation syndrome is a relatively common but easily overlooked cause of chronic open-angle glaucoma. When an eye with pseudoexfoliation develops a secondary trabecular block glaucoma the condition is referred to as ***pseudoexfoliation glaucoma*** or ***glaucoma capsulare***. Although the condition is more common in females than males by a ratio of 3:2, males appear to be more at risk of developing glaucoma. On presentation the pseudoexfoliation is unilateral in about two-thirds of cases. Although no clear hereditary pattern has been established the condition is a particularly common cause of glaucoma in Scandinavia.

PATHOGENESIS

In pseudoexfoliation a grey–white, fibrillogranular material is deposited in and around the anterior segment of the eye. Tissues affected are the anterior lens capsule, iris, anterior chamber angle, zonules, ciliary body, anterior vitreous face and conjunctiva. Secondary trabecular block glaucoma is thought to result from a combination of 'clogging up' of the trabeculum by pseudoexfoliative material and/or pigment released from the iris, as well as trabecular endothelial dysfunction. The origin of the material is believed to be multifocal and it appears to be produced by the equatorial lens capsule, iris pigment epithelium and non-pigmented ciliary epithelium secondary to abnormal basement membrane produced by ageing epithelial cells. It is both histochemically and ultrastructurally similar to amyloid. In addition to its occurrence within the eye, exfoliative fibrillopathy has been reported in skin and visceral organs suggesting that the pseudoexfoliation syndrome may be an ocular manifestation of a systemic disorder.

CLINICAL FEATURES

1. **Slitlamp biomicroscopy**
   (a) The anterior lens surface shows pseudoexfoliative material. The constant rubbing of the pupil scrapes the material off the midzone of the lens giving rise to a central disc (Figure 6.64) with a peripheral band and a clear zone in between (Figure 6.65).
   (b) The pupillary border shows pseudoexfoliative material (Figure 6.66).
   (c) Defects in the pupillary ruff (frill) are also common and increase with age.
   (d) Atrophy of the sphincter gives rise to 'moth-eaten' transillumination defects which are most evident in eyes with pupillary ruff defects (Figure 6.67).
   (e) Pigment dispersion is a frequent finding which should alert the clinician to the possibility of pseudoexfoliation. On the iris sphincter the pigment granules have a whorl-like configuration whereas in the iris periphery they are scattered more diffusely.

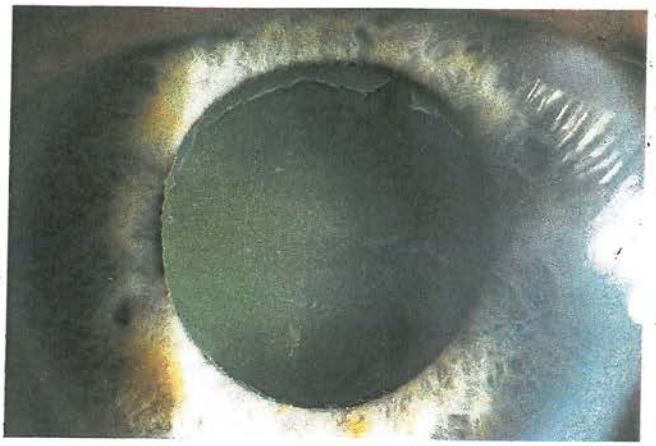

Figure 6.64 Central disc of pseudoexfoliative material



Figure 6.67 Transillumination iris defects in pseudoexfoliation

Figure 6.65 Peripheral band of pseudoexfoliative material

(f) The cornea may show deposits of both pseudoexfoliative material and pigment.
(g) A mild aqueous flare may be seen.

2. **Gonioscopy**
   (a) Trabecular hyperpigmentation is common and is usually most marked inferiorly (Figure 6.68). The pigment lies on the surface of the trabeculum and has a patchy distribution. A scalloped band of pigment running on to or anterior to Schwalbe's line (Sampaolesi line) is also frequently seen.
   (b) A 'dandruff-like' appearance of the trabeculum due to the deposition of pseudoexfoliative material.
   (c) Narrow angles are present in some cases and even in eyes with wide open angles and marked hyperpigmentation, the IOP may become elevated after the pupil is dilated.

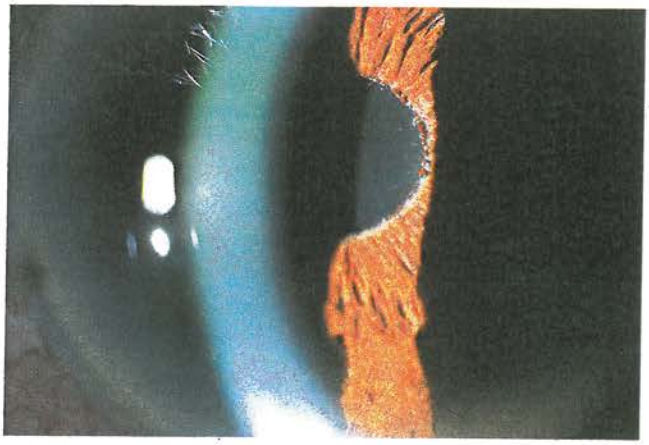

Figure 6.66 Pseudoexfoliative material on the pupillary border

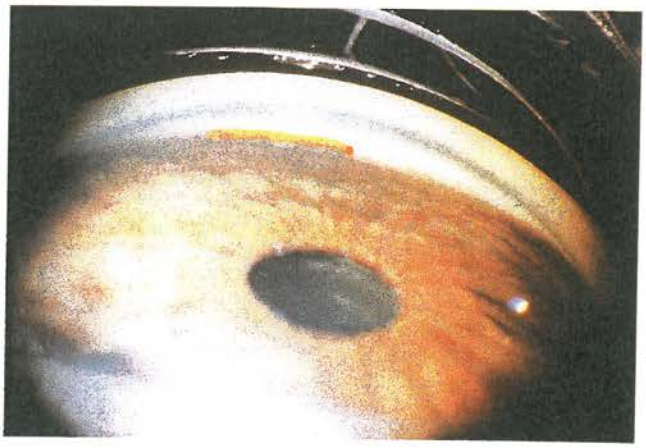

Figure 6.68 Trabecular hyperpigmentation in pseudoexfoliation

3. **The zonules** may be weak and covered with pseudoexfoliative material, and rarely, the lens may spontaneously subluxate. Because of zonular weakness combined with poor dilatation of the pupil extracapsular cataract extraction may be associated with complications such as large zonular dialysis during anterior capsulotomy, capsular rupture, lens dislocation and vitreous loss. The presence of phacodonesis, asymmetry in the depth of the anterior chamber and excessive movement of the lens during anterior capsulotomy should alert the surgeon to this possibility. Following cataract extraction pseudoexfoliative material may be found on the anterior vitreous face, posterior capsule and intraocular lens.

Pseudoexfoliation glaucoma

RISK FACTORS

There are many unresolved questions concerning the relationship between the pseudoexfoliation syndrome and POAG. Most authorities believe that pseudoexfoliative glaucoma is a secondary open-angle glaucoma which differs from POAG. However, others disagree, and are of the opinion that pseudoexfoliation glaucoma is merely a form of POAG. The cumulative risk of raised IOP in an eye with pseudoexfoliation is 5% at 5 years and 15% at 10 years. Because of this low risk, follow-up examinations can be at relatively long intervals (i.e. 9–12 monthly). If one eye has glaucoma and the fellow eye shows pseudoexfoliation, the risk of glaucoma in the fellow eye within 5 years is about 50%. The fellow eye should therefore be watched more frequently (i.e. 3–6 monthly). If the fellow eye does not have pseudoexfoliation the risk of subsequent glaucoma is small.

CLINICAL FEATURES

The age at presentation, usually during the seventh decade of life, is later than POAG. The majority of patients present with chronic open-angle glaucoma which is usually unilateral. Occasionally there is an acute rise of IOP in eyes with wide open angles which must not be confused with primary angle-closure glaucoma. The extent of angle hyperpigmentation correlates with the severity of glaucoma. Patients with glaucoma do not have an increased incidence of steroid responsiveness. The prognosis is less good than in POAG irrespective of therapy because the IOP is usually higher and more difficult to control and visual field loss may also develop more rapidly.

TREATMENT

Because patients with pseudoexfoliation glaucoma frequently have high IOPs with great fluctuations, cupping and visual field loss can develop rapidly. It is therefore important to watch patients with exfoliation glaucoma closely until the IOP is brought under control.

1. **Medical treatment** is the same as for POAG but, despite initial success in most cases, there is a high incidence of late failure and therefore patients are more likely to require subsequent laser therapy or surgery.
2. **Laser trabeculoplasty** is particularly effective, possibly because of trabecular hyperpigmentation. However, after an initial good response a gradual late rise of IOP occurs so that after four years the results are the same as in POAG.
3. **Trabeculectomy** at an early stage may be advantageous. It has the same success rate as in POAG, with no unusual complications.

PIGMENT DISPERSION SYNDROME AND PIGMENTARY GLAUCOMA

Pigment dispersion syndrome

PATHOGENESIS

The pigment dispersion syndrome is usually a bilateral condition characterized by the liberation of pigment granules from the iris pigment epithelium and their deposition throughout the anterior segment. The condition primarily affects whites and may be inherited as an autosomal dominant trait with variable penetrance. Myopia predisposes both to the phenotypical manifestations and the development of a secondary open-angle 'pigmentary' glaucoma. The pigment shedding is caused by the mechanical rubbing of the posterior pigment layer of the iris against packets of lens zonules as a result of excessive posterior bowing of the mid-peripheral portion of the iris. It is also possible that the pigment epithelium itself is abnormal and more susceptible to shedding and in some patients strenuous exercise may precipitate episodes of pigment dispersion associated with a rise in IOP. Elevation of IOP appears to be caused by pigmentary obstruction of the intertrabecular spaces and damage to the trabeculum secondary to denudation, collapse and sclerosis. It has been postulated that the posterior bowing of the peripheral iris is caused by reverse pupil block in which a transient and relative increase in the pressure in the anterior chamber compared with the posterior chamber bows the iris posteriorly and induces irido-zonular touch. This is supported by the observation that the amount of pigment shedding may be diminished by reversing the iris concavity with miotics.

CLINICAL FEATURES

The classical triad of the pigment dispersion syndrome is (a) ***Krukenberg spindle,*** (b) ***iris transillumination defects*** and (c) ***trabecular hyperpigmentation*** (Figure 6.69).

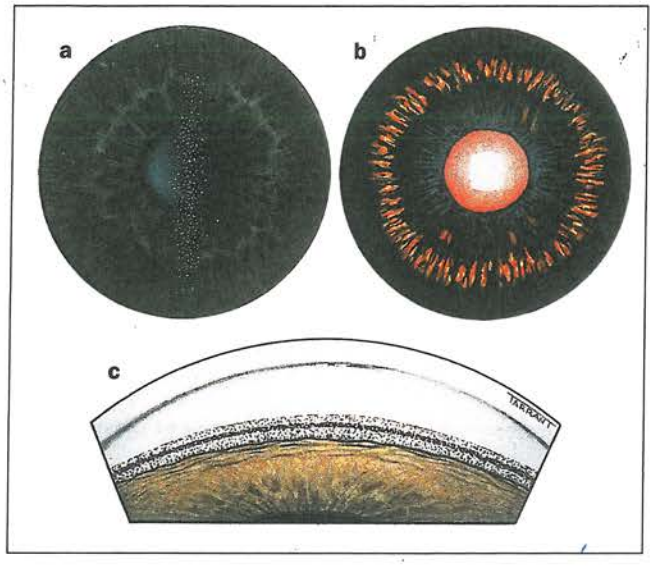

Figure 6.69 Pigment dispersion syndrome. **a**: Krukenberg spindle; **b**; iris transillumination defects; **c**: trabecular hyperpigmentation

1. **Slitlamp biomicroscopy**:
   (a) Krukenberg spindle, which consists of a vertical spindle-shaped deposition of pigment on the corneal endothelium (Figure 6.70). In some cases the pigment is distributed more diffusely. Although a Krukenberg spindle is commonly seen in the pigment dispersion syndrome it is neither universal nor pathognomonic of the condition.

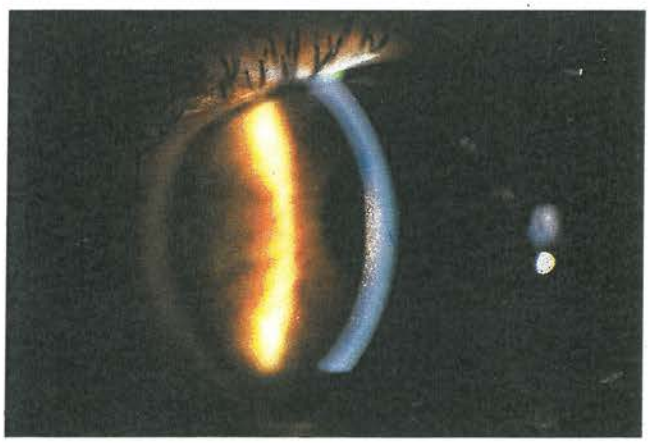

Figure 6.70 Krukenberg spindle in pigment dispersion syndrome

   (b) Fine pigment granules on the anterior surface of the iris which are preferentially deposited within its furrows (Figure 6.71).
   (c) The anterior lens surface may also show pigment deposits. On the posterior lens surface the pigment tends to form a line at the site of vitreolenticular adhesion.

Figure 6.71 Pigment granules on the surface of the iris in the pigment dispersion syndrome

   (d) Iris atrophy resulting from loss of the pigment epithelium from the mid-periphery gives rise to characteristic radial slit-like transillumination defects (Figure 6.72). Iris transillumination is performed with the slit beam narrowed to 1 mm and set coaxially with the slitlamp microscope. The light is then shone through the pupil and the iris examined under low magnification.
   (e) Very deep anterior chamber (Figure 6.73).
2. **Gonioscopy**
   (a) Wide open angle.



Figure 6.72 Iris transillumination defects involving the midperiphery in the pigment dispersion syndrome

Figure 6.73 Deep anterior chamber in pigment dispersion syndrome

(b) Concavity of the peripheral iris near its insertion.

(c) Trabecular hyperpigmentation (Figure 6.74). The pigmentation is most marked over the posterior trabeculum and forms a dense band involving the entire circumference of the meshwork uniformly. On closer inspection the fine pigment granules lie both on and within the trabeculum. Pigment may also be seen on, or anterior to Schwalbe line.

3. **Ophthalmoscopy** of the peripheral retina may show areas of lattice degeneration.

Figure 6.74 Trabecular hyperpigmentation in the pigment dispersion syndrome

Pigmentary glaucoma

INCIDENCE OF GLAUCOMA

Up to 50% of patients with the pigment dispersion syndrome eventually develop chronic open-angle glaucoma. Men are affected more frequently than women by a 2:1 ratio. It is therefore very important to follow regularly all patients with the condition, particularly myopic males with Krukenberg spindles. However, the initial IOP, cup–disc ratio and degree of trabecular hyperpigmentation are not helpful in identifying those who will eventually develop raised IOP and glaucoma. Patients with pigmentary glaucoma have an increased incidence of steroid responsiveness as compared with the general population.

CLINICAL FEATURES

1. **Presentation** is usually between the third and fourth decades although in women the glaucoma tends to develop ten years later than in men.
2. **The symptoms** are the same as those found in POAG, although occasionally the sudden release of pigment granules following vigorous movement of the pupil or strenuous physical exercise may precipitate an acute rise in IOP resulting in corneal oedema and haloes.
3. **The IOP** may initially be very unstable, so that a single normal reading does not necessarily rule out the possibility of glaucoma. Some patients have much higher levels and fluctuations of IOP than those with POAG, and at the time of diagnosis it is common to find advanced disease in one eye and relatively mild damage in the other.
4. **The long-term prognosis** is relatively good and with the passage of time the control of IOP becomes easier. In a few cases there is a spontaneous resolution of glaucoma which may or may not be associated with a decrease in trabecular pigmentation.

DIFFERENTIAL DIAGNOSIS

1. **POAG** may be associated with a hyperpigmented trabeculum but the pigment tends to be more segmental than in pigment dispersion syndrome. Patients with POAG are also usually older and they lack Krukenberg spindles and iris transillumination defects.
2. **Pseudoexfoliation glaucoma** may show trabecular hyperpigmentation and pigment dispersion in the anterior segment. However, transillumination defects are evident at the margin of the pupil rather than in the periphery. In contrast to pigmentary glaucoma, pseudoexfoliative glaucoma usually affects patients over the age of 60 years, is unilateral in 50% of cases and has no predilection for a myopic refractive error.
3. **Pseudophakic pigmentary glaucoma,** in which the rubbing of the haptics and optics of a posterior chamber intraocular lens against the posterior iris results in pigment dispersion and outflow obstruction.

TREATMENT

1. **Medical treatment** is similar to that of POAG although miotics may, theoretically, be of particular benefit because they not only increase aqueous outflow but also have the added benefit of decreasing irido-zonular contact.
2. **Laser trabeculoplasty** is initially effective in most cases although younger patients appear to respond better than older individuals. It is important not to over-treat eyes with heavily pigmented angles and to start at a relatively low power laser setting. At least one third of patients will require trabeculectomy within five years of laser trabeculoplasty.
3. **Trabeculectomy** may be required in patients unresponsive to medical therapy and laser trabeculoplasty although in the younger age group the results are less predictable than in older patients. A higher percentage of patients with pigmentary glaucoma require surgery as compared with POAG and men require it at an earlier age than women.

NEOVASCULAR GLAUCOMA

Introduction

PATHOGENESIS

Neovascular glaucoma is a relatively common and extremely serious condition which frequently results in severe visual impairment. The common factor in most eyes with neovascular glaucoma is severe, diffuse and chronic retinal ischaemia. It has been postulated that hypoxic retinal tissue produces heparin-binding growth factors in an attempt to revascularize hypoxic areas. These factors induce the development of secondary neovascularization on the retina (proliferative retinopathy) and are also capable of diffusing into the anterior segment where they initiate neovascularization of the iris (rubeosis iridis). The subsequent invasion of the angle by fibrovascular tissue results in elevation of IOP as a result of impairment of aqueous outflow. The fibrovascular membrane later contracts to produce a secondary angle-closure glaucoma. It should be emphasized that rubeosis iridis is not synonymous with neovascular glaucoma because in some cases rubeosis is non-progressive and it may even regress spontaneously.

CAUSES

1. **Ischaemic central retinal vein occlusion** is the most common cause of neovascular glaucoma, accounting for 36% of cases. Approximately 50% of eyes with ischaemic central retinal vein occlusion develop neovascular glaucoma within 3 months ('100-day glaucoma'). However, occasionally the interval may be as short as four weeks and as long as two years.
2. **Diabetes mellitus** is also an important cause of neovascular glaucoma, accounting for 32% of cases. Patients with longstanding diabetes (ten years or more) who also have proliferative diabetic retinopathy are at particular risk. The risk of glaucoma is decreased by appropriate panretinal photocoagulation but is increased by cataract extraction, particularly if intracapsular, or by pars plana vitrectomy when undertaken in an eye with an ischaemic retina or when inadequate laser therapy has been applied. The crucial period for the development of rubeosis iridis after cataract extraction is the first three to four weeks. It is therefore extremely important to observe the patient frequently during that period.
3. **Miscellaneous causes**
   (a) Carotid obstructive disease accounts for 13% of cases.
   (b) Central retinal artery occlusion (4% of cases).
   (c) Intraocular tumours (1% of cases).
   (d) Longstanding retinal detachment (1% of cases).
   (e) Chronic intraocular inflammation (0.5% of cases).

CLASSIFICATION

Although there is a certain amount of overlap, it is convenient to divide neovascular glaucoma into the following three stages:

1. **Rubeosis iridis.**
2. **Secondary open-angle glaucoma.**
3. **Secondary synechial angle-closure glaucoma.**

Rubeosis iridis

CLINICAL FEATURES

The earliest finding is the presence of tiny dilated capillary tufts or red spots at the pupillary margin. This sign may be easily missed unless the iris is examined carefully under high magnification. The new blood vessels (Figure 6.75) then grow radially over the surface of the iris towards the angle, sometimes joining dilated blood vessels at the collarette. At this stage the IOP is normal and the new vessels may regress either spontaneously or with treatment. Angle neovascularization in the absence of pupillary involvement may occur. It is therefore important to perform careful gonioscopy in eyes at high risk even when the pupil and iris are uninvolved.

TREATMENT

1. **Panretinal photocoagulation** has a high degree of success in inducing regression of the new vessels and preventing the subsequent progression to glau-

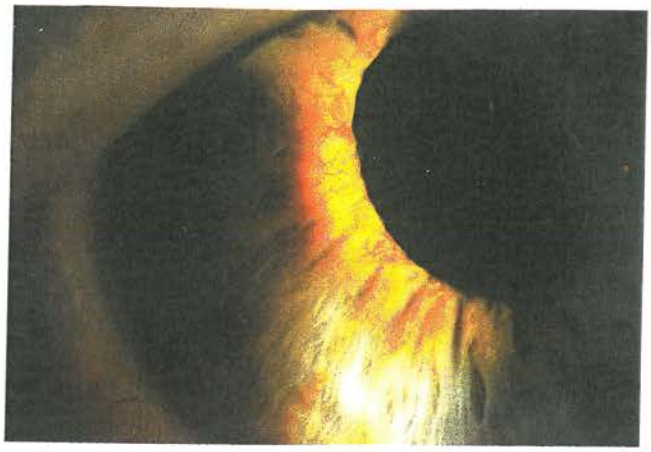

Figure 6.75 Early rubeosis iridis

coma. Eyes with ischaemic central retinal vein occlusion may require 2000–3000, 500 µm burns.

2. **Retinal surgery**: if the rubeosis is present following vitrectomy in a diabetic patient with residual retinal detachment, further attempts at retinal reattachment should be made because if the retina is flat the rubeosis will frequently regress. In these cases additional retinal photocoagulation will also be beneficial.

Secondary neovascular open-angle glaucoma

CLINICAL FEATURES

The new blood vessels continue to grow across the iris surface and join the circumferential ciliary body artery. The neovascular tissue then proliferates across the face of the ciliary body and scleral spur to invade the angle (Figure 6.76). In the angle the new blood vessels arborize and form a fibrovascular membrane which blocks the trabeculum and gives rise to a secondary open-angle glaucoma.

TREATMENT

1. **Medical treatment** is the same as for POAG but miotics should be avoided. Topical atropine 1% and intensive topical steroids should be given to reduce inflammation.
2. **Panretinal photocoagulation** should be performed in all cases even if the IOP is adequately controlled medically, although it should be remembered that this will not influence the fibrous component of the fibrovascular membrane.



Figure 6.76 Early angle neovascularization

Secondary neovascular angle-closure glaucoma

CLINICAL FEATURES

The fibrovascular tissue in the angle contracts and pulls the peripheral iris over the trabeculum in a zipper-like fashion. The main clinical features of advanced NVG are:

1. Severely reduced visual acuity.
2. Congestion of the globe and pain.
3. Very high IOP and corneal oedema.
4. Aqueous flare due to leakage of proteins from the iris new vessels.
5. Severe rubeosis iridis (Figure 6.77).
6. Distortion of the pupil and ectropion uveae due to radial contraction of fibrovascular tissue are late changes (Figure 6.78).

Figure 6.77 Severe rubeosis iridis

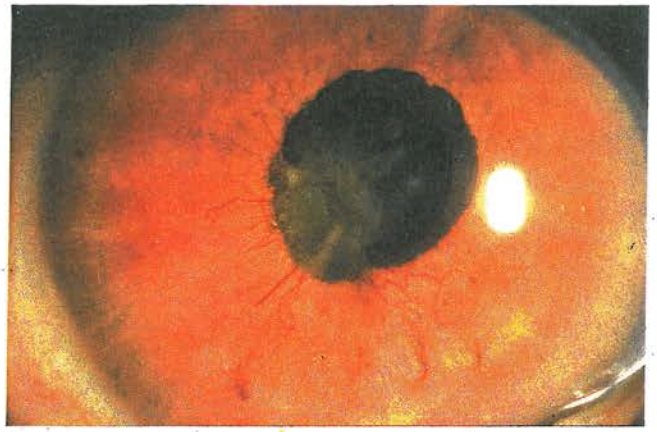

Figure 6.78 Distortion of the pupil and ectropion uveae in an eye with severe rubeosis iridis

7. Gonioscopy shows synechial angle closure with inability to see any of the angle structures posterior to Schwalbe line (Figure 6.79).

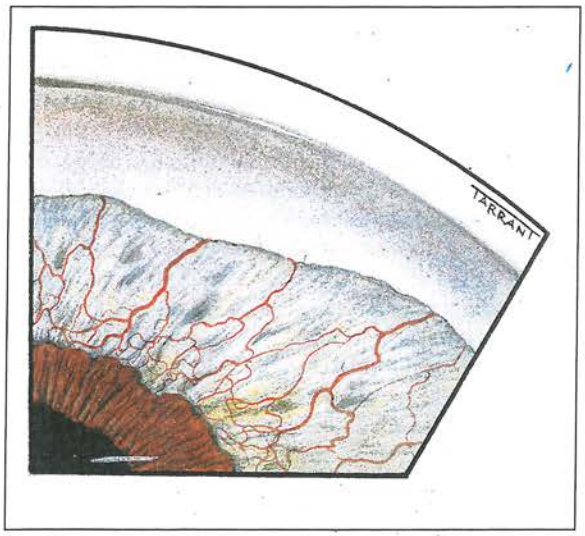

Figure 6.79 Total synechial angle closure

DIFFERENTIAL DIAGNOSIS

1. **Primary acute congestive angle-closure glaucoma.** Occasionally patients with neovascular glaucoma may have a sudden onset of pain and congestion which mimics primary angle-closure glaucoma. Although the cloudy cornea may make gonioscopy difficult, it is usually possible to detect rubeosis iridis after the corneal oedema has been cleared with topical glycerine. Gonioscopy of the fellow eye to demonstrate a normal angle appearance should also help in differential diagnosis.
2. **Postvitrectomy inflammation** in diabetic patients may be associated with congested and prominent iris vasculature and a transient rise in IOP which may be mistaken for neovascular glaucoma. However, these features usually resolve following the intensive administration of topical steroids.

TREATMENT

At this stage the visual prognosis is extremely poor and the main aim of treatment is to relieve pain and congestion.

1. **Medical treatment** with topical atropine and intensive topical steroids will decrease the amount of inflammation and make the eye more comfortable and less congested, even if the IOP remains high. Beta-blockers can also be helpful when used in combination with atropine and steroids in keeping the eye comfortable but miotics and sympathomimetics are contraindicated as thay may increase discomfort.
2. **Artificial filtering shunts** may be successful in some cases, provided the initial visual acuity is better than 'hand movements'. Although the IOP can be significantly reduced, many eyes subsequently lose light perception or become phthisical, so that the main benefit is pain relief.
3. **Cyclodestructive procedures** such as cyclocryotherapy and trans-scleral laser (YAG or diode) are helpful in keeping the eye comfortable when used in conjunction with medical therapy. They are usually indicated when all hope of salvaging useful vision is lost as they may intensify the amount of ocular ischaemia and lead to phthisis bulbi.
4. **Retrobulbar alcohol injection** is very useful in relieving pain but it may cause permanent ptosis and does not relieve congestion.
5. **Enucleation** may be the only solution if all else fails.

INFLAMMATORY GLAUCOMAS

Introduction

CLASSIFICATION

Glaucomas secondary to intraocular inflammation frequently present a considerable diagnostic and therapeutic challenge. Although in some cases the elevation of IOP is transient and innocuous, frequently it is persistent and severely damaging. The four main types are:

1. **Angle closure with pupil block.**
2. **Angle closure without pupil block.**
3. **Open angle.**
4. **Specific hypertensive uveitis syndromes.**
   Fuchs uveitis syndrome
   Posner–Schlossman syndrome

DIAGNOSTIC PROBLEMS

1. **Monitoring of IOP** is important because clinicians may be so preoccupied with suppressing the intraocular inflammation that they may fail to suspect the presence of raised IOP.
2. **Fluctuations of IOP** may be dramatic in eyes with compromised outflow facility associated with chronic anterior uveitis. Patients with borderline IOPs should therefore be admitted to hospital for phasing.
3. **Ciliary body shutdown** may occur in acute anterior uveitis or an acute exacerbation of chronic anterior uveitis and result in a temporary decrease in aqueous secretion due to inflammation of the secretory ciliary epithelium. The finding of a normal or even a subnormal IOP may therefore lull the clinician into a false sense of security. A return of ciliary body function due to a decrease in uveitis activity may subsequently be associated with a rise in IOP in an eye with a permanently compromised outflow facility. It is therefore important to perform gonioscopy on all eyes with chronic anterior uveitis and to continue monitoring the IOP and the appearance of the optic disc as the inflammation resolves.
4. **The mechanisms** of elevation of IOP may be uncertain and occasionally more than one mechanism may be responsible. In patients who are steroid responders, the IOP may become elevated as the acute inflammation is being brought under control.

Secondary angle-closure glaucoma with pupil block

PATHOGENESIS

Secondary angle closure is caused by 360° iridolenticular adhesions (seclusio pupillae). The pupil block obstructs the passage of aqueous humour from the posterior to the anterior chamber, and the increased pressure in the posterior chamber causes an anterior bowing of the peripheral iris (iris bombé). If severe, iris bombé is associated with a shallowing of the anterior chamber and apposition of the peripheral iris to the trabeculum and peripheral cornea. If this occurs in an eye with active inflammation, the iris sticks to the trabeculum and the iridocorneal contact becomes permanent with the development of peripheral anterior synechiae (PAS). Angle-closure glaucoma with pupil block is now relatively uncommon. In fact, most eyes with seclusio pupillae have a normal or subnormal IOP due to concomitant chronic ciliary body shutdown.

CLINICAL FEATURES

1. **Slitlamp biomicroscopy** shows seclusio pupillae, iris bombé and shallow anterior chamber (Figures 6.80 and 6.81**b**).
2. **Gonioscopy** shows angle closure from iridotrabecular contact (Figure 6.81**a**).
3. **Indentation gonioscopy** with a Zeiss four-mirror goniolens, or equivalent, may be used in assessing the extent of appositional as opposed to synechial angle closure (*see* Figures 6.22).

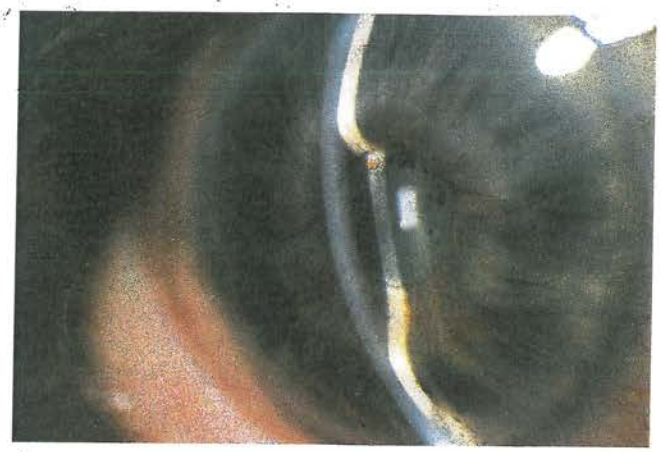

Figure 6.80 Secondary angle-closure glaucoma caused by pupil block. Iris bombé is present and the anterior chamber is very shallow

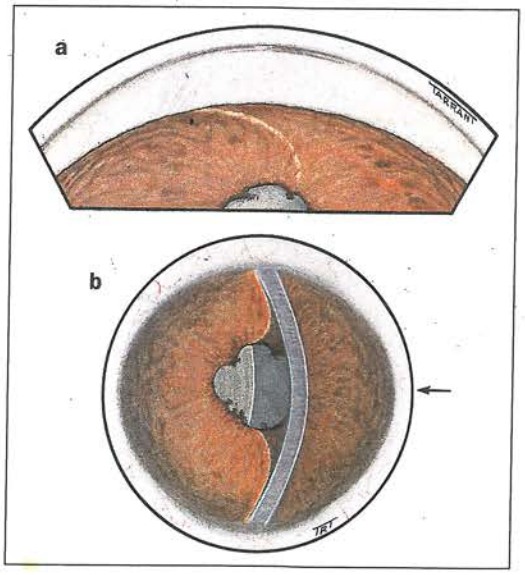

Figure 6.81 Inflammatory secondary angle-closure caused by pupil block. **a**: gonioscopic view; **b**: slitlamp view

TREATMENT

1. **Topical treatment** with aqueous suppressants may be effective in relatively mild cases with IOPs less than 30 mmHg.
2. **Systemic acetazolamide** is usually required if the IOP is >30 mmHg.

3. **Hyperosmotic agents** (mannitol, isosorbide, glycerol) are less effective in lowering IOP in an inflamed eye than in one with primary acute angle-closure glaucoma.
4. **Laser iridotomy** is performed to re-establish the communication between the posterior and anterior chambers. This will only eliminate the element of pupil block and will therefore only be effective in lowering IOP if at least 25% of the angle is still open. It is recommended that several large openings are made and the patient is examined at frequent intervals to ensure that they remain patent.
5. **Surgical iridectomy** should be considered if the laser iridectomy closes.

Secondary angle-closure glaucoma without pupil block

PATHOGENESIS

Chronic anterior uveitis causes the deposition of inflammatory debris in the angle, subsequent organization and contraction of which pulls the peripheral iris over the trabeculum thereby causing a gradual and progressive synechial angle closure (Figure 6.82). Eyes with pre-existing narrow angles may be more at risk than those with wide open angles. Eyes with granulomatous inflammation with inflammatory nodules in the angle may also be more prone to secondary angle closure than those with non-granulomatous uveitis.

CLINICAL FEATURES

Secondary angle closure unassociated with pupil block is a frequent cause of raised IOP in eyes with chronic anterior uveitis. As the angle becomes progressively compromised, the rise in IOP is usually gradual. Even severe elevations of IOP of >50 mmHg may be asymptomatic.

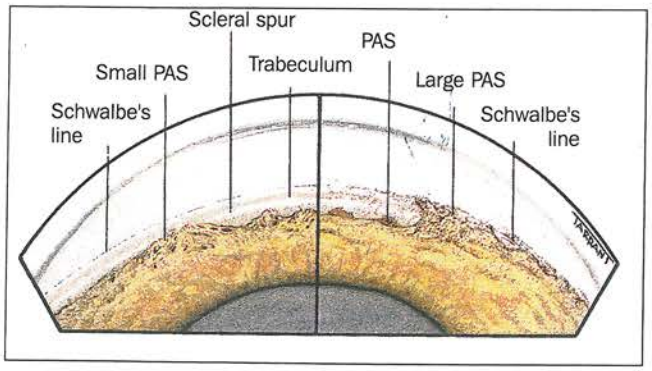

Figure 6.82 Partial angle closure by peripheral anterior synechiae

1. **Slitlamp biomicroscopy** shows a deep anterior chamber.
2. **Gonioscopy** shows peripheral anterior synechiae (Figure 6.83).

It should be remembered that exacerbations of intraocular inflammation in eyes with chronic iridocyclitis are frequently associated with a lowering of IOP. Even glaucomatous eyes with a moderate elevation of IOP (30–35 mmHg) may become hypotonous during acute exacerbations of uveitis. It is therefore extremely important to pay particular attention to the IOP as the uveitis is being brought under control.

Figure 6.83 Extensive peripheral anterior synechiae

TREATMENT

1. **Non-intervention** may be prudent in eyes with relatively mild uveitis for fear of upsetting the delicate balance between diminished aqueous outflow and decreased inflow secondary to relative ciliary body shutdown.
2. **Medical treatment** is the same as for secondary angle closure associated with pupil block.
3. **Trabeculectomy** may be successful, particularly when combined with adjunctive antimetabolites.
4. **Cyclodestructive procedures** may be tried if all else fails.

Secondary open-angle glaucoma

PATHOGENESIS IN ACUTE ANTERIOR UVEITIS

During the acute phase of anterior uveitis, the IOP is usually normal or subnormal due to concomitant ciliary

shutdown. Occasionally, however, a secondary open-angle glaucoma develops due to obstruction of aqueous outflow, most commonly just as the acute inflammation is subsiding and ciliary body function is returning to normal. This effect, which is transient and fairly innocuous, may be steroid-induced or caused by a combination of the following mechanisms:

1. **Trabecular obstruction** by inflammatory cells and debris which may be associated with increased aqueous viscosity due to the leakage of proteins from the inflamed iris blood vessels.
2. **Acute trabeculitis** associated with inflammation and oedema of the trabecular meshwork and a secondary reduction of intertrabecular pores may result in a reduction in outflow facility. It is thought that acute trabeculitis is the probable cause of raised IOP in eyes with anterior uveitis associated with herpes zoster and herpes simplex
3. **Prostaglandins** may be associated with raised IOP, although the exact mechanism is uncertain.

PATHOGENESIS IN CHRONIC ANTERIOR UVEITIS

The main mechanism for reduced outflow facility is thought to be trabecular scarring and/or sclerosis secondary to chronic trabeculitis. The exact incidence and importance of this mechanism is, however, difficult to determine with accuracy as most eyes also have some degree of synechial angle closure.

CLINICAL FEATURES

Due to the variable appearance of the angle on gonioscopy, a definitive diagnosis of elevated IOP as a result of trabecular damage is difficult. In theory, the angle should be open and, in some eyes, a gelatinous exudate resembling 'mashed potatoes' is seen on the trabeculum.

TREATMENT

1. **In acute anterior uveitis** the IOP usually returns to normal once the inflammation has subsided.
2. **In chronic anterior uveitis** treatment is the same as for secondary synechial angle-closure glaucoma.

Glaucoma in Fuchs uveitis syndrome

CLINICAL FEATURES

Fuchs uveitis syndrome (FUS) is an idiopathic, unilateral, chronic, non-granulomatous, anterior uveitis with an insidious onset. The clinical features of this condition are described in Chapter 7. The most common complication is cataract and the most serious is glaucoma. Although there is no effective treatment for FUS, patients should be examined at six-monthly intervals in order to detect glaucoma which eventually affects about 30% of cases. In 50% of patients with glaucoma the complication is detected at presentation and the subsequent conversion rate to glaucoma is 0.5% per year. In some patients, glaucoma is precipitated by cataract surgery. Initially the rise of IOP is intermittent before becoming chronic. In the majority of cases the glaucoma is of the open-angle type and is thought to be caused by trabecular sclerosis.

TREATMENT

1. **Topical therapy** is successful in controlling up to a third of patients.
2. **Trabeculectomy** is required in unresponsive cases but because the success rate is less favourable than in POAG, adjunctive antimetabolite therapy at the time of surgery is recommended.

Posner–Schlossman syndrome

CLINICAL FEATURES

The Posner–Schlossman syndrome (glaucomatocyclitic crisis) is characterized by recurrent attacks of unilateral, acute secondary open-angle glaucoma associated with mild anterior uveitis. The cause of the raised IOP is presumed to be acute trabeculitis. This very rare condition typically affects young adults, 40% of whom are positive for HLA-Bw54. Males are affected more frequently than females. The IOP is elevated for between a few hours to several days and may cause haloes around lights due to corneal oedema, but pain is rare. The attacks are unilateral, although 50% of patients have bilateral involvement at different times. The intervals between attacks vary in length and, with the passage of time, they usually become longer. In rare cases, a chronic elevation of IOP develops which may lead to cupping of the optic disc and loss of visual field.

1. **Slitlamp biomicroscopy** during an acute attack shows the following:
   (a) Externally the eye is white or minimally injected.
   (b) Corneal epithelial oedema is usually present, with a few fine white central keratic precipitates (Figure 6.84).
   (c) IOP is usually very high (40–80 mmHg).
   (d) A few aqueous cells may be present.
2. **Gonioscopy** shows an open angle and unless it is performed the condition may be confused with acute primary angle-closure glaucoma. The absence of PAS helps in the differentiation from other inflammatory glaucomas.

Figure 6.84 Corneal epithelial oedema and fine keratic precipitates in Posner–Schlossman syndrome

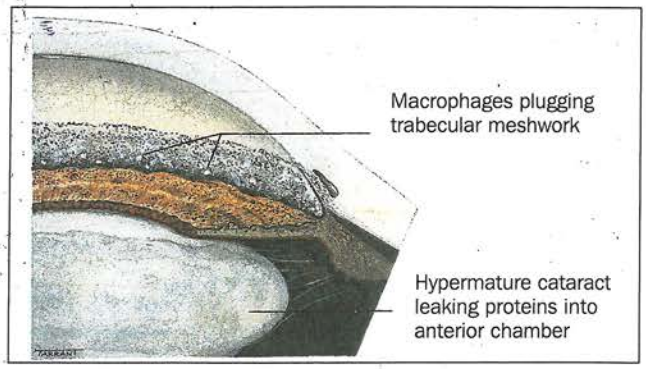

Figure 6.85 Pathogenesis of phacolytic glaucoma

TREATMENT

Treatment of an acute attack is with topical steroids to control the inflammation and aqueous suppressants for the raised IOP. Oral indomethacin may also be beneficial.

MISCELLANEOUS SECONDARY GLAUCOMAS

Phacolytic glaucoma

PATHOGENESIS

Phacolytic glaucoma (lens protein glaucoma) is a secondary open-angle glaucoma which occurs in eyes with hypermature cataracts. It is caused by trabecular obstruction by high-molecular-weight, soluble lens proteins which have leaked through an intact capsule into the aqueous humour. Macrophages which have phagocytosed some of the proteins may also contribute to trabecular blockage (Figure 6.85). Phacolytic glaucoma should not be confused with phacoanaphylactic (phacoantigenic) uveitis which is an autoimmune granulomatous reaction to lens proteins occurring in an eye with a ruptured capsule.

CLINICAL FEATURES

Phacolytic glaucoma is more likely to occur in underdeveloped countries, where patients with cataract frequently present late.

1. **Slitlamp biomicroscopy** shows the following:
   (a) A unilateral hypermature cataract is evident (Figure 6.86).

Figure 6.86 Morgagnian cataract in an eye with phacolytic glaucoma

   (b) The anterior chamber is deep and the aqueous may contain floating white particles (Figure 6.87).
   (c) Rarely, in advanced cases, numerous particles may form a 'pseudohypopyon' (Figures 6.88, 6.89).

Figure 6.87 Hypermature cataract and floating white particles in the anterior chamber in an eye with phacolytic glaucoma

Figure 6.88 Corneal vascularization, small pseudohypopyon and white particles in the anterior chamber in an eye with longstanding phacolytic glaucoma

Figure 6.89 Very large pseudohypopyon in an eye with severe phacolytic glaucoma

2. **Gonioscopy** shows an open angle but macrophages containing ingested lens material may be present.

TREATMENT

Once the IOP has been controlled medically the cataract should be removed. The proteinaceous material should be first flushed out of the eye and an extracapsular extraction performed. Posterior chamber lens implantation is safe but care must be taken not to rupture the zonules when performing an anterior capsulotomy.

Phacomorphic glaucoma

CLINICAL FEATURES

Phacomorphic glaucoma is an acute secondary angle-closure glaucoma precipitated by an intumescent cataractous lens. Just like phacolytic glaucoma, it is more commonly encountered in underdeveloped countries. A history of gradual impairment of vision or an increase in myopia may be obtained. Presentation is similar to acute PACG with a very shallow anterior chamber and dilated pupil (Figure 6.90). A lens opacity is usually evident with obvious lens swelling. Examination of the fellow eye will demonstrate a deep anterior chamber and an open angle, thus making the diagnosis of PACG unlikely.

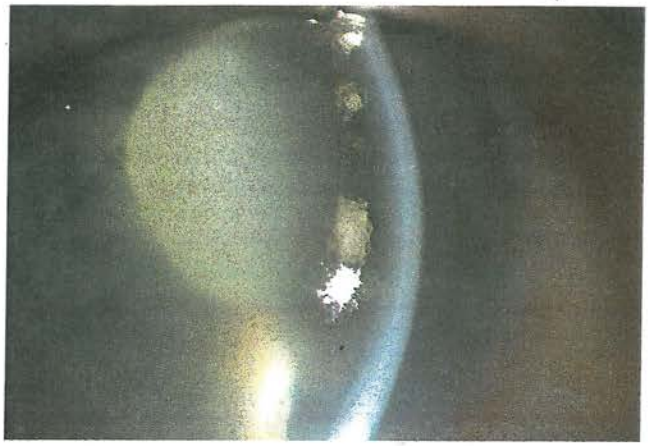

Figure 6.90 Corneal oedema, shallow anterior chamber, and intumescent cataract in an eye with phacomorphic glaucoma

TREATMENT

1. **Initial medical therapy** is similar to acute PACG. Intensive topical steroids should also be administered to control the inflammatory response.
2. **Laser iridotomy** is performed once the IOP is controlled.
3. **Cataract extraction** can be performed once the eye is quiet. Although extracapsular cataract extraction with posterior chamber lens implantation may be successful, it carries an increased risk of capsular rupture and vitreous loss. A surgical peripheral iridectomy should always be performed.

Red cell glaucoma

PATHOGENESIS

Following traumatic hyphaema, secondary elevation of IOP is caused by blockage of the trabeculum by red blood cells. In some cases the blood clot may also occlude the pupil and an angle closure component may be superimposed. A secondary haemorrhage may develop within three to five days of the initial injury which is frequently more severe than the primary bleed. The rate of re-bleeding is about 5%. Patients with sickle-cell haemoglobinopathies

are at increased risk of developing complications associated with traumatic hyphaema.

COMPLICATIONS

Although most traumatic hyphaemas are relatively innocuous and transient, in some patients severe and prolonged elevation of IOP may damage the optic nerve and cause blood staining of the cornea. The latter can progress very rapidly and may take a long time to clear. The optic nerve is endangered with IOP >50 mmHg for two days. The size of the hyphaema is a good indication as to the visual prognosis and risk of complications as follows:

1. **Hyphaema involving less than half** the anterior chamber is associated with a 4% incidence of raised IOP, a 22% incidence of complications and a final visual acuity of > 6/18 occurs in 78% of eyes.
2. **Hyphaema involving more than half** the anterior chamber is associated with an 85% incidence of raised IOP, 78% incidence of complications and a final visual acuity of >6/18 occurs in only 28% of eyes.

TREATMENT

1. **Medical treatment** is with beta-blockers, carbonic anhydrase inhibitors or hyperosmotic agents, depending on the level of IOP.
2. **Surgical evacuation** of the blood with or without trabeculectomy is indicated in the following circumstances:
   (a) An IOP of >50 mmHg for 2 days or >35 mmHg for 7 days.
   (b) Early corneal blood staining, because it can progress to a dense opacity within a few hours.
   (c) Total hyphaema for more than five days – to prevent the development of peripheral anterior synechiae which may lead to chronic secondary glaucoma.

Post-traumatic angle recession glaucoma

PATHOGENESIS

Angle recession glaucoma occurs as a result of blunt traumatic damage to the trabecular meshwork. Angle recession is detected gonioscopically as an irregular widening of the ciliary body band (Figure 6.91) and is a sign of damage to the anterior face of the ciliary body (Figure 6.92). Although a large percentage of eyes with traumatic hyphaema also show some evidence of angle recession, only 6–9% develop glaucoma after ten years. It is thought that the rise in IOP is secondary to trabecular damage and not from the angle recession itself. However, the larger the area of recessed angle the higher the risk of glaucoma. Because glaucoma may not develop until many months or even years after the initial injury, all patients with a recessed angle should be examined periodically.

Figure 6.91 Gonioscopic view of angle recession showing irregular widening of the ciliary body band

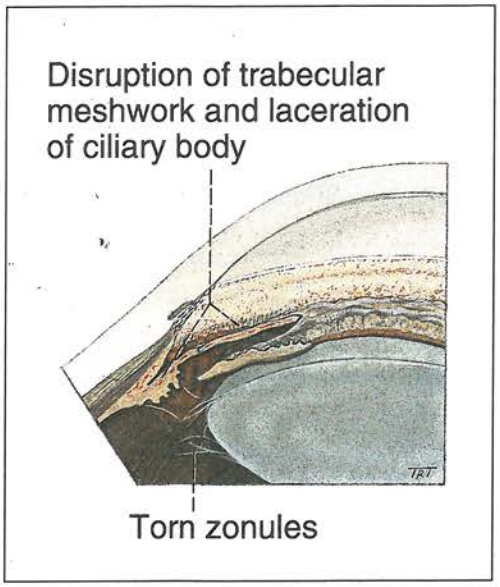

Figure 6.92 Angle recession

CLINICAL FEATURES

The diagnosis should be considered in any patient with unilateral chronic glaucoma. The condition may be easily missed unless a careful past history is taken and the following signs of past trauma are elicited:

1. **Slitlamp biomicroscopy:**
   (a) Anterior chamber may be slightly deeper than in the fellow eye.
   (b) The pupil may be larger than in the fellow eye due to post-traumatic mydriasis. It may also show small rents with absence or detachment of the pupillary ruff (frill).
   (c) Iridodialysis (Figure 6.93).

Figure 6.93 Traumatic iridodialysis

2. **Gonioscopy** may show an irregular, scarred and recessed angle with pigment within the recess (Figure 6.94). In some longstanding cases, the cleft becomes obscured by fibrous tissue. On cursory examination, the hyperpigmentation in the angle may be mistaken for pigmentary glaucoma, particularly if the corneal endothelium is also covered by pigment granules. It is important to compare the angle appearance in the two eyes and also to compare parts of the angle in the same eye.

TREATMENT

1. **Medical treatment** is the same as for other types of secondary open-angle glaucoma but it is frequently unsatisfactory and laser trabeculoplasty is ineffective.
2. **Trabeculectomy** with adjunctive antimetabolite therapy is the most effective surgical procedure.
3. **An artificial filtering shunt** should be considered if trabeculectomy fails.

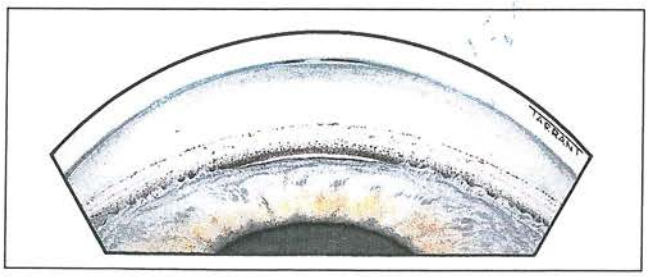

Figure 6.94 A scarred recessed angle

Ghost cell glaucoma

PATHOGENESIS

In ghost cell glaucoma there is trabecular obstruction by degenerate red blood cells that pass from the vitreous into the anterior chamber. After two weeks in the vitreous, haemoglobin leaks out of the red blood cells and they turn into degenerate 'ghost cells' which then pass through a defect in the anterior vitreous face into the anterior chamber. Because their normal pliability is lost, they become entrapped within the pores of the trabeculum and obstruct aqueous outflow. Ghost cell glaucoma occurs in three different settings:

1. When a cataract extraction is complicated by a large vitreous haemorrhage and hyphaema, the red blood cells in the anterior chamber clear, but those in the vitreous persist and turn into ghost cells that pass into the anterior chamber. This is the most common type.
2. Ghost cells pass into the anterior chamber following cataract extraction in an eye with a pre-existing vitreous haemorrhage.
3. Vitreous haemorrhage in an eye that is already aphakic or pseudophakic.

CLINICAL FEATURES

Ghost cells may be recognized as reddish-brown or khaki particles in the aqueous (Figure 6.95). They should not be confused with white cells as this may inadvertently lead to the excessive use of topical steroids and antibiotics.

TREATMENT

1. **Medical treatment** is initially prescribed.

Figure 6.95 Ghost cell glaucoma

2. **Irrigation** of the anterior chamber should be performed and the ghost cells washed out if medical therapy fails.
3. **Posterior vitrectomy** with irrigation may be required in selected cases.

Iridocorneal endothelial syndrome

PATHOGENESIS

The iridocorneal endothelial (ICE) syndrome typically affects one eye of a young to middle-aged woman. It consists of the following three very rare and frequently overlapping disorders:

1. **Progressive iris atrophy.**
2. **Iris naevus (Cogan–Reese) syndrome.**
3. **Chandler syndrome.**

The common link in the ICE syndrome is the presence of an abnormal corneal endothelial cell layer which has the capacity to migrate across the anterior chamber angle and onto the surface of the iris. The ICE syndrome may progress to glaucoma or corneal decompensation or both. Glaucoma is caused by secondary synechial angle closure as a result of contraction of the abnormal tissue. Some have suggested the term 'proliferative endoepitheliopathy' to describe this disorder. Polymerase chain reaction evidence shows that herpes simplex virus DNA is present in a substantial percentage of ICE syndrome corneal specimens. This suggests that the condition may have a viral origin.

CLINICAL FEATURES

1. **Slitlamp biomicroscopy**
   (a) Corectopia – distortion of the pupil.
   (b) Pseudopolycoria – a 'second' pupil (Figure 6.96) in a previously normal iris.
   (c) Iris atrophy of varying severity (Figures 6.97, 6.98 and 6.99).

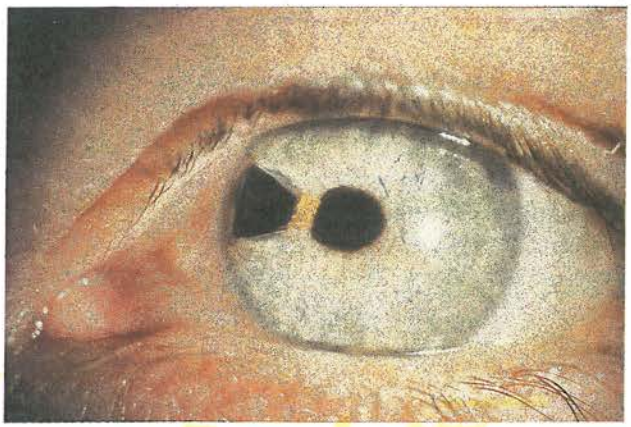

Figure 6.96 A second pupil (pseudopolycoria) in progressive iris atrophy

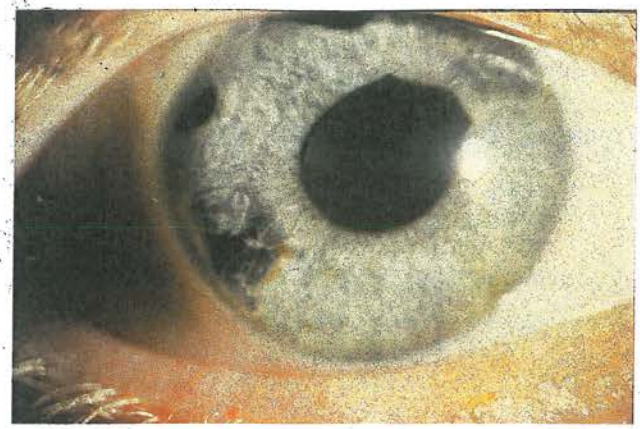

Figure 6.97 Atrophy of the stroma in progressive iris atrophy

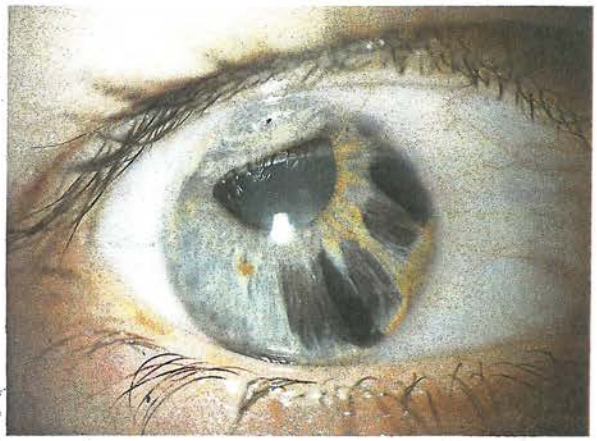

Figure 6.98 Displacement of the pupil (corectopia) and severe full-thickness atrophy of the stroma in progressive iris atrophy

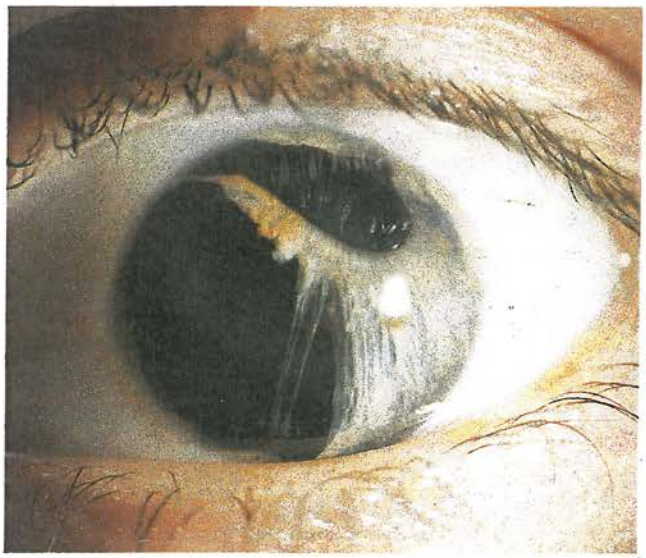

Figure 6.99 Very advanced iris changes in progressive iris atrophy

(d) The corneal endothelium has a 'hammered-silver' appearance (Figure 6.100) similar to Fuchs dystrophy when viewed in specular reflected light with the slit-lamp. Corneal oedema secondary to endothelial decompensation is present in more advanced cases.

2. **Gonioscopy** shows broad-based peripheral anterior synechiae that often extend anterior to Schwalbe line (Figure 6.101).
3. **Glaucoma** occurs in about 50% of cases.



Figure 6.100 'Hammered-silver' appearance of the corneal endothelium in Chandler syndrome

Figure 6.101 Extensive peripheral anterior synechiae in progressive iris atrophy

THREE SYNDROMES

In their purest form, the three syndromes are easily distinguished from each other. However, there is frequently considerable overlap and a clear differentiation may be difficult. Occasionally, during follow-up one condition can change into another. In general, differentiation depends primarily on the iris changes, as follows:

1. **Progressive iris atrophy** is characterized by severe iris changes with stromal atrophy, hole formation and marked displacement of the pupil towards areas of PAS (Figure 6.102). In between areas of atrophy the stroma appears normal.

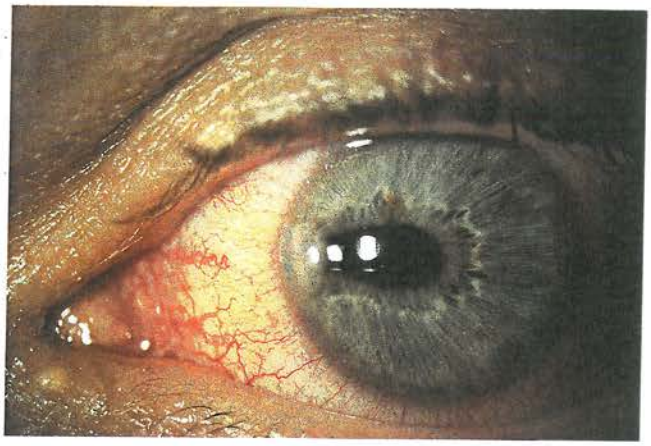

Figure 6.102 Displacement of the pupil towards the site of peripheral anterior synechiae in progressive iris atrophy

2. **The iris naevus** (Cogan–Reese) syndrome is characterized by either a diffuse naevus which covers the anterior iris (Figure 6.103), or pigmented, pedunculated iris nodules (Figure 6.104). The normal pattern of the iris surface appears smudged and matted. Iris atrophy is absent in 50% of cases and in the remainder it is usually mild to moderate, although corectopia may be severe in some cases. It is important not to misdiagnose a diffuse iris melanoma for the iris naevus syndrome.

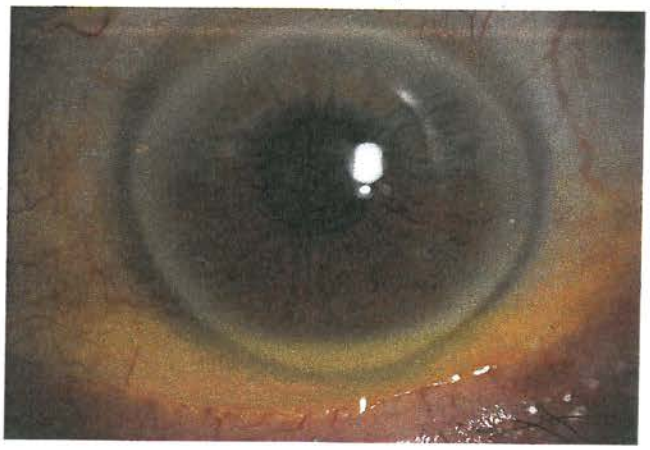

Figure 6.103 Diffuse iris naevus in Cogan–Reese syndrome

3. **Chandler syndrome** is characterized by severe corneal changes (Figure 6.105) and frequently presents with blurred vision and haloes due to corneal oedema. Stromal atrophy is absent in about 60% of

Figure 6.104 Pigmented iris nodules in Cogan–Reese syndrome

Figure 6.105 Severe corneal changes in Chandler syndrome

cases and in the remainder its severity is variable; corectopia is mild to moderate. Glaucoma is usually less severe than in the other two syndromes, and at presentation the IOP may be normal.

TREATMENT

1. **Medical treatment** of glaucoma is ineffective in a large proportion of cases.
2. **Trabeculectomy**, even when combined with adjunctive antimetabolite therapy, is frequently unsuccessful because of late-onset bleb failure.
3. **Artificial filtering shunts** are eventually required in many cases.

Iridoschisis

PATHOGENESIS

Iridoschisis is a rare condition which affects the elderly and is often bilateral. It is associated with underlying angle-closure glaucoma in about 90% of cases. It has been postulated that acute or intermittent angle closure results in iris atrophy because of the high IOP.

CLINICAL FEATURES

1. **Slitlamp biomicroscopy** shows the following:
   (a) Round and mobile pupil.
   (b) Shallow anterior chamber (Figure 6.106).
   (c) Iridoschisis which usually involves the inferior iris. The severity ranges from intrastromal atrophy (Figure 6.107) to extensive splitting of the anterior leaf (Figure 6.108). In advanced cases the disintegrated iris fibrils may float freely in the anterior chamber.
   (d) A localized corneal opacity (Figure 6.109) may develop at the site of touch between the strands and the corneal endothelium. Rarely the cornea decompensates.
2. **Gonioscopy** shows a narrow occludable angle which may be associated with peripheral anterior synechiae.

Figure 6.106 Shallow anterior chamber in iridoschisis

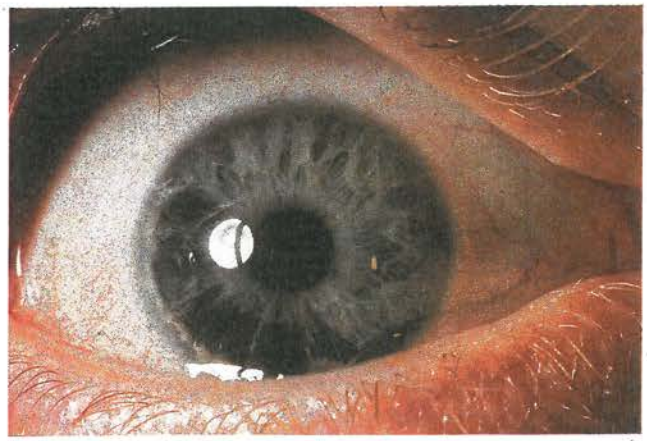

Figure 6.107 Intrastromal atrophy in iridoschisis

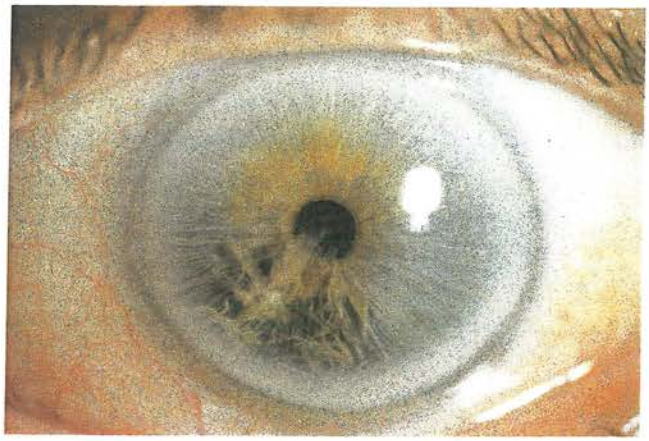

Figure 6.108 Splitting of the anterior leaf of the iris in iridoschisis

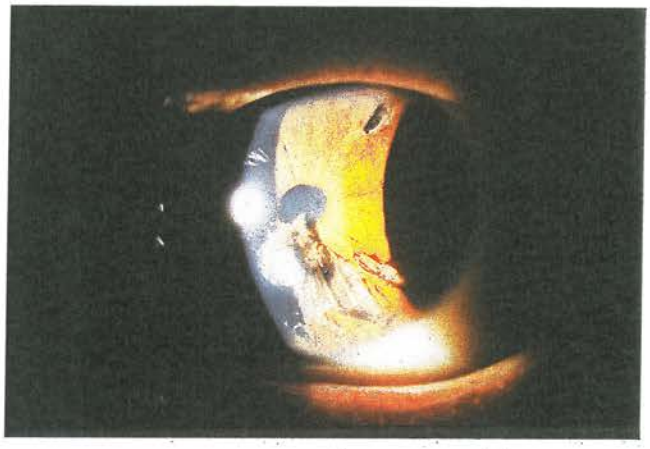

Figure 6.109 Severe iridoschisis with extensive splitting of the anterior leaf of the iris, iridocorneal contact with a localized corneal opacity – note the peripheral iridotomy performed for angle-closure glaucoma

TREATMENT

1. Initial treatment is laser iridotomy for pupillary block.
2. Subsequent treatment is aimed at preventing either the development or progression of glaucomatous damage.

CONGENITAL GLAUCOMAS

Primary congenital glaucoma

PATHOGENESIS

Although primary congenital glaucoma (PCG) is the most common of the congenital glaucomas, it is still a very rare condition, affecting only 1:10 000 births; 65% of patients are boys. Most cases of PCG are sporadic. In approximately 10% the inheritance is autosomal recessive with incomplete penetrance. Aqueous outflow is impaired as a result of an 'isolated trabeculodysgenesis' which is defined as a maldevelopment of the trabeculum, including the iridotrabecular junction, which is not associated with any other major ocular anomalies. Clinically, trabeculodysgenesis is characterized by absence of the angle recess with the iris inserted directly into the surface of the trabeculum. This iris insertion can be either flat or concave.

1. **Flat iris insertion** is one in which the iris inserts flatly and abruptly into the thickened trabeculum at or anterior to the scleral spur. Even when the iris inserts anterior to the scleral spur, it is often still possible to visualize a portion of the ciliary body (Figure 6.110**a**).
2. **Concave iris insertion** is one in which the superficial iris tissue sweeps over the iridotrabecular junction and the trabeculum. In contrast to eyes with a flat iris insertion, the scleral spur and the ciliary body are obscured by the overlying iris tissue which is either sheet-like or consists of a dense arborizing meshwork (Figure 6.110**b**). It is less common than the flat iris insertion.

The clinical features depend on the age of onset and the level of IOP. Both eyes are affected in 75% of cases, although the severity of involvement is frequently asymmetrical.

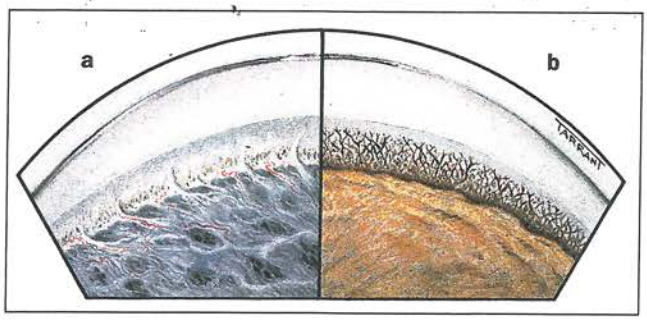

Figure 6.110 Trabeculodysgenesis in primary congenital glaucoma. **a**: flat anterior iris insertion; **b**: concave iris insertion

CLASSIFICATION

According to the age of onset, PCG can be classified into the following three types:

1. **True congenital glaucoma** (40% of cases), in which the IOP becomes elevated during intrauterine life.
2. **Infantile glaucoma** (55% of cases), in which the disease becomes manifest prior to the child's third birthday.
3. **Juvenile glaucoma**, the least common. Here the pressure rise develops after the third birthday but before

the age of 16 years. In these cases the clinical manifestations may simulate POAG. In some patients gonioscopy is normal whilst in others trabeculodysgenesis is present.

CLINICAL FEATURES

1. **Corneal haze** is frequently the first sign noticed by the parents. It is caused by epithelial oedema and corneal clouding secondary to raised IOP and it may be associated with lacrimation, photophobia and blepharospasm.
2. **Buphthalmos** describes a large eye as a result of elevated IOP prior to the age of three years (Figure 6.111). It is not usually reported by the parents unless it is unilateral and advanced. As the sclera enlarges it also becomes thinner and takes on a blue appearance due to enhanced visualization of the underlying uvea. If the cornea continues to enlarge the anterior chamber will deepen and, in advanced cases, the zonules may become stretched and rarely the lens may subluxate. The ocular enlargement also causes axial myopia which may give rise to anisometropic amblyopia.

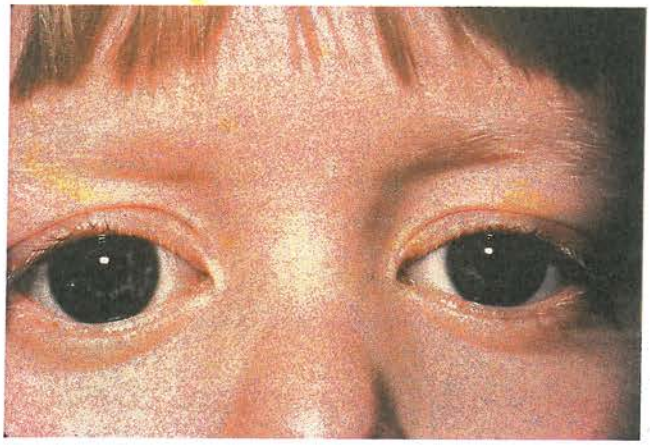

Figure 6.111 Bilateral buphthalmos involving right eye more than left

3. **Breaks in Descemet membrane** may be associated with endothelial decompensation and a sudden influx of aqueous into the corneal stroma. Chronic stromal oedema may lead to permanent corneal scarring. Haab striae represent healed breaks in Descemet membrane and appear as curvilinear lines (Figures 6.112, 6.113).
4. **Optic disc cupping** in infants may occur early but it may regress once the IOP is normalized. In most normal infants there is no apparent central cup in the optic nerve head and very few have a cup–disc ratio greater than 0.3. A high percentage of infants with PCG have a cup–disc ratio greater than 0.3. In contrast to an adult eye with a high IOP, the scleral canal in an infant eye enlarges with a high IOP as part of the generalized enlargement of the globe and the lamina cribrosa may bow posteriorly. In infants, the cup–disc ratio may be increased either from neuronal loss or enlargement of the scleral canal, or both.

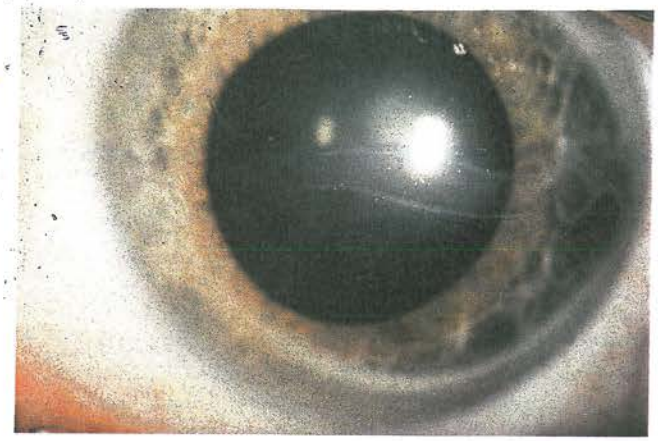

Figure 6.112 Haab striae



Figure 6.113 Haab striae seen against the red reflex

DIFFERENTIAL DIAGNOSIS

1. **Cloudy cornea at birth** may be caused by the following conditions:
   (a) Birth trauma may give rise to corneal decompensation as a result of breaks in Descemet's membrane.
   (b) Intrauterine rubella may give rise to a cloudy cornea at birth due to keratitis. It should be noted that 10% of infants with the rubella syndrome also have congenital glaucoma due to an angle anomaly similar to that in PCG. The glaucoma may be missed because the eye may not be significantly enlarged because of pre-existing microphthalmos.

(c) Metabolic disorders such as mucopolysaccharidoses and mucolipidoses.

2. **Large cornea** may also be caused by:
   (a) Megalocornea.
   (b) Very high myopia (rare).
3. **Lacrimation** resulting from delayed canalization of the nasolacrimal duct.
4. **Secondary infantile glaucoma** may be associated with the following conditions:
   (a) Tumours such as retinoblastoma and juvenile xanthogranuloma.
   (b) Persistent hyperplastic primary vitreous.
   (c) Retinopathy of prematurity.
   (d) Intraocular inflammation.
   (e) Trauma.
   (f) Ectopia lentis.

MANAGEMENT

The management of PCG is always surgical and presents a difficult long-term problem. Because of its relative rarity it should be managed by an ophthalmologist who is familiar with the surgical techniques that may be required to control the IOP. The initial evaluation should be performed under general anaesthesia using intravenous ketamine because other agents may falsely lower IOP. Examination of optic discs should be undertaken first, followed by measurement of IOP and corneal diameters, and finally gonioscopy.

1. **The IOP** is measured with either the Perkins (*see* Figure 6.10) or Schiotz tonometer (*see* Figure 6.9).
2. **The corneal diameters** are measured in vertical and horizontal meridians with the same calipers that are used during strabismus surgery. In normal infants, most of the increase in horizontal corneal diameter occurs within the first year of life. At six months of age the mean corneal diameter is less than 10 mm and at one year is less than 12 mm. The adult horizontal corneal diameter of 12.5 mm is usually attained by the third birthday. For this reason, a corneal diameter greater than 12 mm prior to the age of one year or 13 mm at any age should be viewed with suspicion. Diameters of 14 mm are typical of advanced buphthalmos.
3. **Surgery**
   (a) ***Goniotomy*** (Figure 6.114) is performed at the initial examination if the diagnosis is confirmed provided there is sufficient corneal clarity and the angle can be visualized. Although the procedure may have to be repeated, the eventual success rate is about 85%. Goniotomy is unlikely to be effective if the corneal diameter is around 14 mm because in these eyes the canal of Schlemm is already obliterated.
   (b) ***Trabeculotomy*** (Figure 6.115) may be necessary either when corneal clouding prevents visualization of the angle or when repeated goniotomy has failed.
   (c) ***Trabeculectomy*** is successful in a significant percentage of cases, particularly when combined with trabeculotomy.
4. **Follow-up**. After the initial surgery further examination under general anaesthesia is performed one month later. It is extremely important to detect and treat refractive errors and amblyopia. The IOP and corneal diameters should also be measured at regular intervals. Progressive enlargement of the corneal dia-

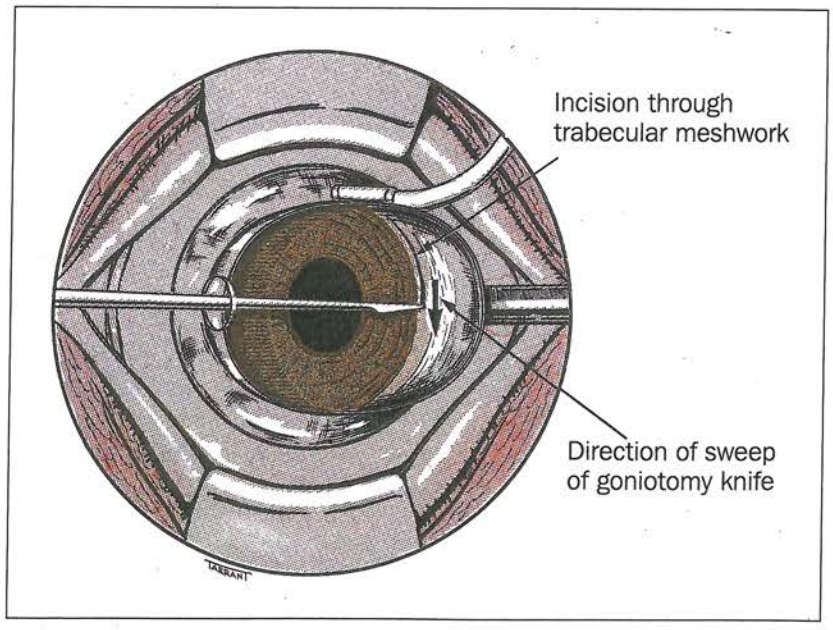

Figure 6.114 Technique of goniotomy for primary congenital glaucoma. An incision is made at the midpoint of the superficial layers of the trabeculum

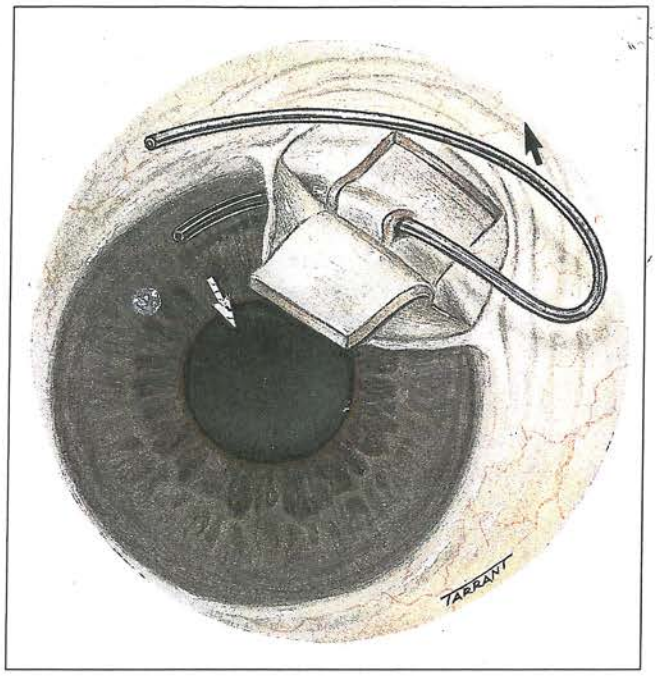

Figure 6.115 Technique of trabeculotomy for primary congenital glaucoma. A trabeculotome is inserted into Schlemm canal and then rotated into the anterior chamber

meter is as important a sign of uncontrolled congenital glaucoma as is progressive visual field loss in adult glaucoma. About 50% of patients develop visual loss from optic nerve damage, anisometropic amblyopia, corneal scarring, cataract and lens subluxation. A buphthalmic eye is also susceptible to traumatic damage.

Iridocorneal dysgenesis

Iridocorneal dysgenesis consists of the following overlapping rare congenital disorders involving the cornea and iris, some of which may be associated with glaucoma. These conditions occur as a result of an abnormality in fetal neural crest cell development.

1. **Axenfeld-Rieger syndrome.**
2. **Peters anomaly.**
3. **Aniridia.**

AXENFELD–RIEGER SYNDROME

The term Axenfeld–Rieger syndrome is used to describe clinical variations within a spectrum of rare developmental disorders. In current nomenclature these conditions are designated by the three following eponyms:

1. **Axenfeld anomaly** which is characterized by a prominent and anteriorly displaced Schwalbe line (posterior embryotoxon, Figure 6.116) onto which are attached strands of peripheral iris tissue (Figure 6.117). ***Glaucoma*** is a very rare association.
2. **Rieger anomaly** is inherited as an autosomal dominant trait with a high degree of penetrance. It is characterized by the following features which are usually bilateral but not always symmetrical:
   (a) Posterior embryotoxon – in some cases Schwalbe line may become detached into the anterior chamber.
   (b) Angle anomalies in mild cases are similar to those found in Axenfeld anomaly. In severe cases, broad leaves of the iris stroma adhere to the cornea anterior to Schwalbe line (Figure 6.118).
   (c) Iris anomalies include: stroma hypoplasia and corectopia (Figure 6.119), pseudopolycoria (Figure 6.120), and ectropion uveae (Figure 6.121).

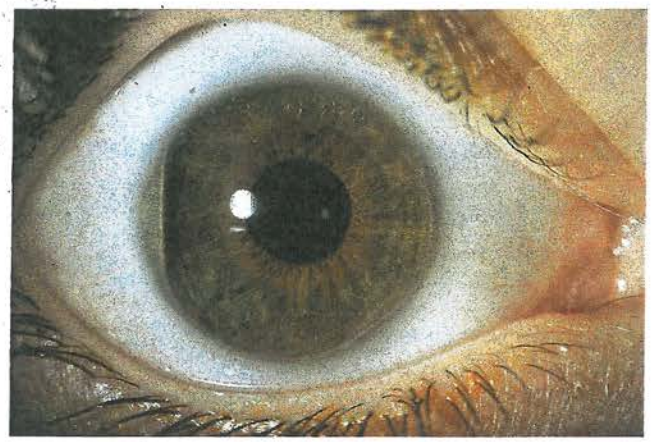

Figure 6.116 Posterior embryotoxon most marked temporally where Descemet membrane is partially detached

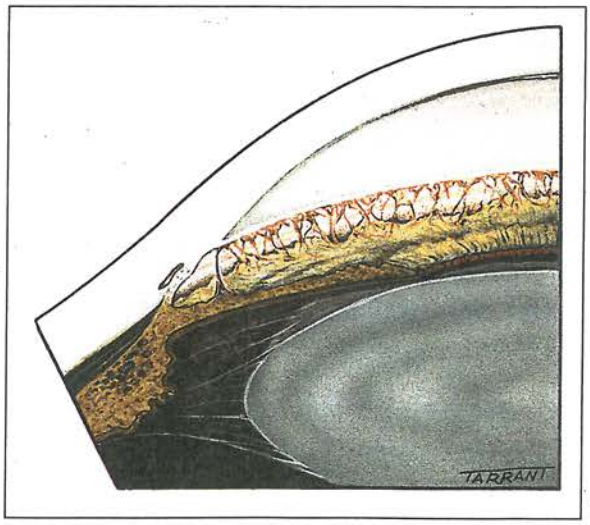

Figure 6.117 Gonioscopic appearance of Axenfeld anomaly showing strands of peripheral iris attached to posterior embryotoxon

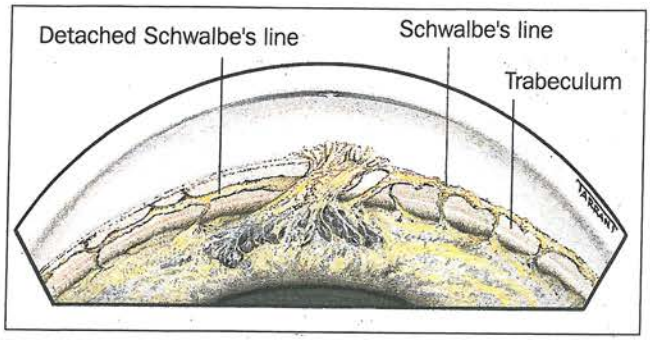

Figure 6.118 Gonioscopic appearance in Rieger anomaly showing peripheral anterior synechiae and partial detachment of Descemet membrane

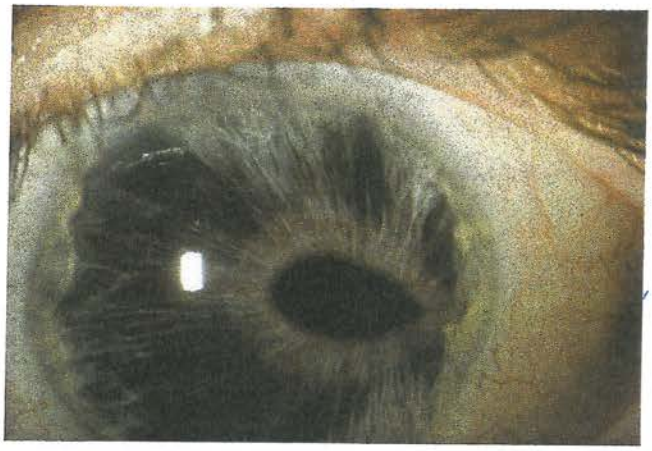

Figure 6.119 Corectopia and stromal iris atrophy in Rieger anomaly

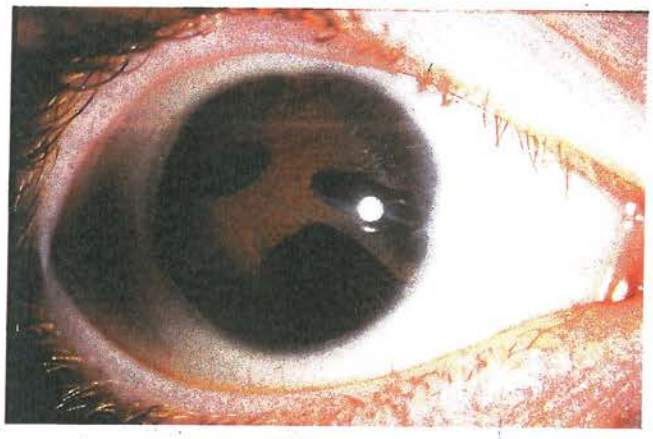

Figure 6.120 Corectopia and full-thickness iris atrophy in Rieger anomaly

(d) ***Glaucoma*** develops in about 50% of cases, usually during early childhood or early adulthood as a result of an associated angle anomaly or secondary synechial angle closure. The elevation of IOP is initially managed medically although surgery may be required in resistant cases.

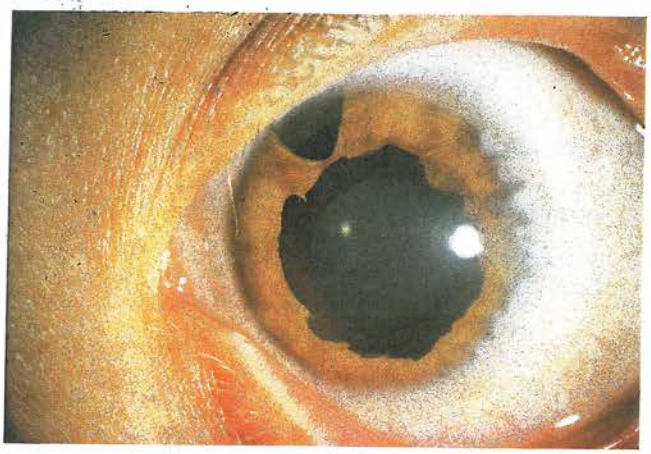

Figure 6.121 Ectropion uveae in Rieger anomaly

3. **Rieger syndrome** is linked to the region of the epidermal growth factor gene on chromosome 4. It is characterized by Rieger anomaly in association with the following non-ocular malformations:
   (a) Dental anomalies consisting of hypodontia (few teeth) and microdontia (small teeth) (Figure 6.122).

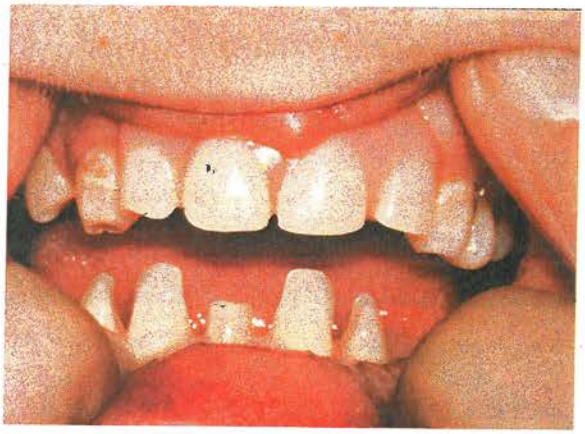

Figure 6.122 Dental abnormalities in Rieger syndrome

   (b) Facial anomalies include: hypoplasia of the maxilla, broad nasal bridge, telecanthus (lateral displacement of medial canthi) and hypertelorism (increased interorbital distance).
   (c) Miscellaneous anomalies include: redundant paraumbilical skin and defects in the region of the pituitary gland.

PETERS ANOMALY

Peters anomaly is an extremely rare but very serious developmental anomaly which is bilateral in 80% of cases. Most cases are sporadic, although autosomal recessive inheritance and chromosomal defects have been described.

1. **Clinical features**
   (a) Corneal opacity is the most striking feature (Figure 6.123). It may be associated with the following: iridocorneal adhesion to its margin (Figure 6.124**a**), keratolenticular apposition (Figures 6.124**b**, and 6.125), attenuation or absence of Descemet membrane, and keratolenticular strands with or without iris adhesions.
   (b) Miscellaneous occasional anomalies include: microphthalmos, cornea plana, sclerocornea, corectopia, iris hypoplasia and anterior polar cataract.
2. **Glaucoma** occurs in about 50% of cases. It is caused by an associated angle anomaly and is frequently present at birth.

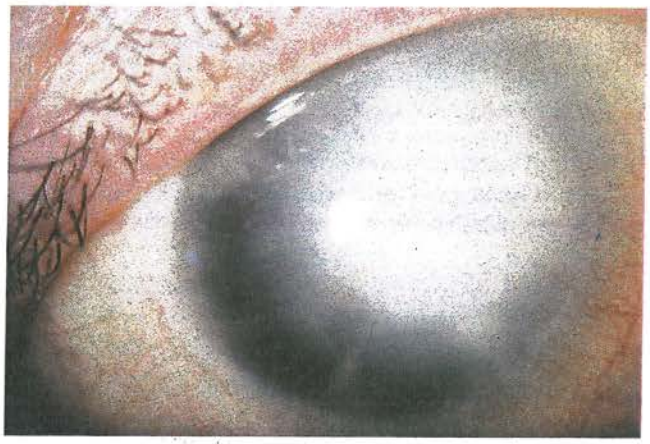

Figure 6.123 Corneal opacity in Peters anomaly

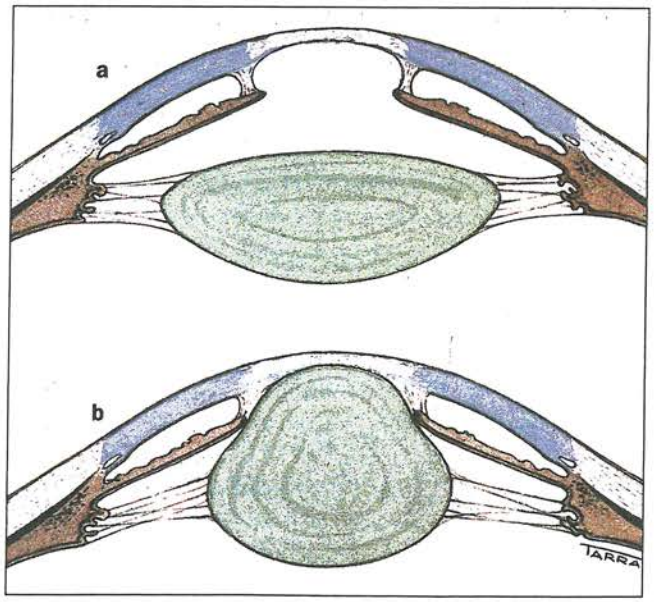

Figure 6.124 Spectrum of changes in Peters anomaly. **a**: iridocorneal adhesions; **b**: keratolenticular apposition

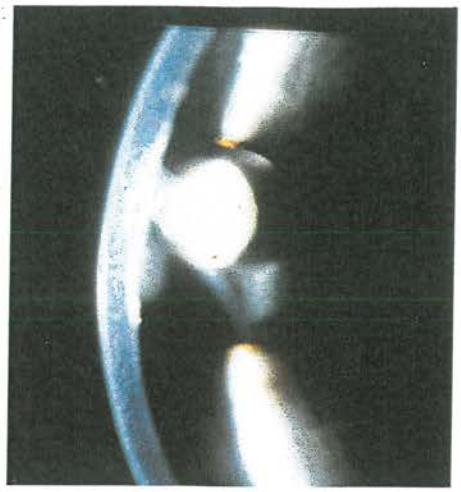

Figure 6.125 Keratolenticular apposition in Peters anomaly

ANIRIDIA

Aniridia is a rare bilateral condition which occurs as a result of abnormal neuroectodermal development secondary to a mutation in the PAX6 (or aniridia) gene on the short arm of chromosome 11.

1. **Classification** – aniridia (AN) can be subdivided into the following three phenotypes:
   (a) **AN-1** (isolated) is dominantly inherited and accounts for 85% of cases.
   (b) **AN-2** (Miller syndrome), which accounts for 13% of cases. It is characterized by deletion of the short arm of chromosome 11 and is associated with Wilm tumour of the kidney, genitourinary anomalies, and mental retardation.
   (c) **AN-3** (Gillespie syndrome) is recessively inherited and accounts for the remaining 2%. It is associated with mental handicap and cerebellar ataxia.
2. **Ocular features**
   (a) The degree of aniridia can vary from partial (Figure 6.126) to total absence (Figure 6.127). However, even in severe cases some iris remnants can be seen on gonioscopy (Figure 6.128).
   (b) Corneal lesions include: opacity, epibulbar dermoids, microcornea, sclerocornea and keratolenticular adhesions.
   (c) Lenticular changes include: opacity (Figure 6.129), subluxation (Figure 6.130), congenital absence, and persistent pupillary membranes.
   (d) Fundus lesions include: foveal hypoplasia, disc hypoplasia and choroidal colobomas.
3. **Glaucoma** develops in about 75% of patients in late childhood or early adolescence.
   (a) The mechanism of glaucoma is synechial angle closure secondary to the pulling forward of rudimentary iris tissue by contraction of pre-existing fibres that bridge the angle (Figure 6.131).

Figure 6.126 Partial aniridia

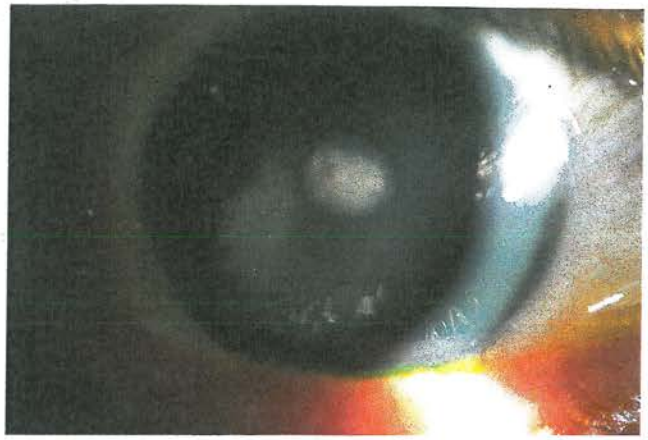

Figure 6.129 Lens opacity in aniridia

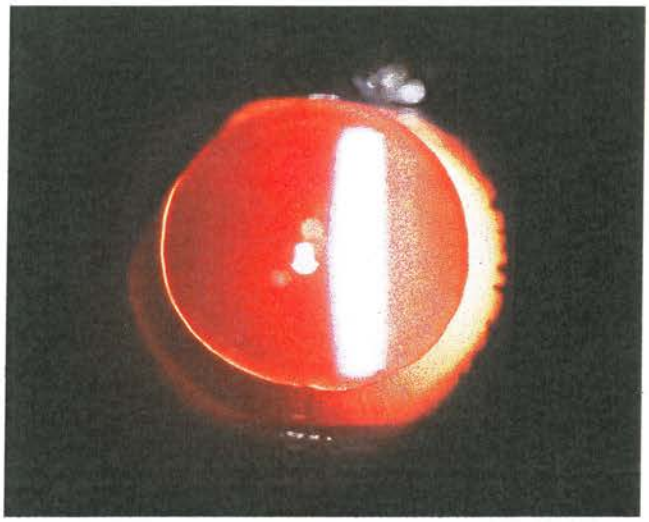

Figure 6.127 Total aniridia

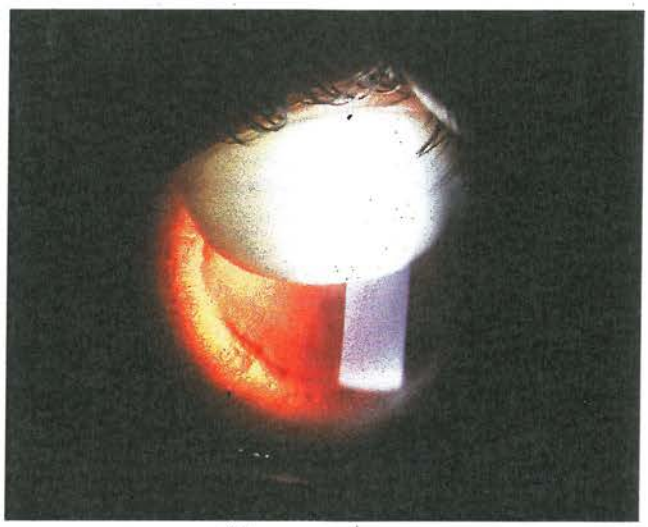

Figure 6.130 Upward subluxation of a cataractous lens in aniridia

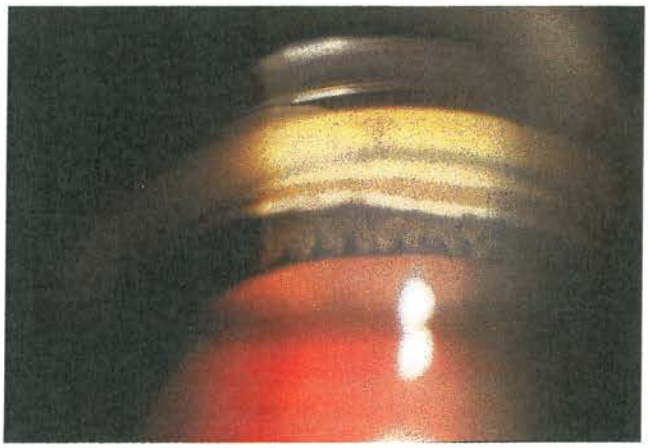

Figure 6.128 Gonioscopic view of aniridia showing remnants of the iris root

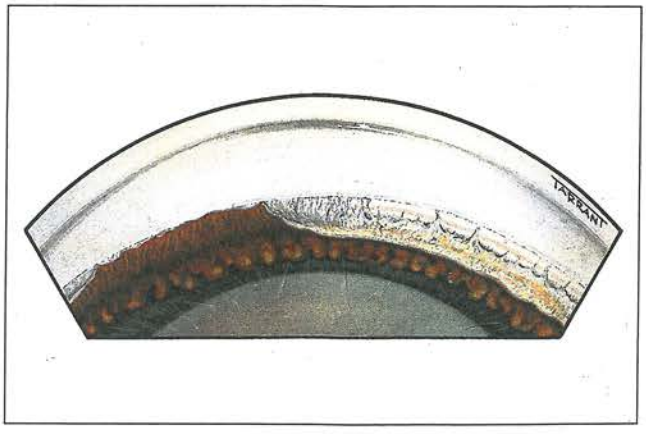

Figure 6.131 Gonioscopic view showing partial synechial angle closure in aniridia

(b) Treatment is difficult and the visual prognosis is guarded. Medical therapy is the safest approach, although this eventually proves inadequate in most cases. Disinsertion of the iris root from the trabecular meshwork may prevent a subsequent rise in IOP if performed before the development of irreversible synechial angle closure. Artificial filtering shunts may be effective in established cases.

Glaucoma in phacomatoses

STURGE–WEBER SYNDROME

Sturge–Weber syndrome (encephalotrigeminal angiomatosis) is characterized by naevus flammeus and intracranial leptomeningeal angiomata (*see* Chapter 8). Glaucoma develops in about 45% of patients on the side corresponding to the facial haemangioma. Patients in whom the lesion affects the upper eyelid are at increased risk of glaucoma.

1. **Presentation** of glaucoma in 60% of patients is within the first two years of life with buphthalmos (Figure 6.132). In the remainder the rise in IOP does not occur until late childhood or early adulthood.
2. **The mechanism** of the glaucoma is controversial. An isolated trabeculodysgenesis may be responsible in infants whereas raised episcleral venous pressure associated with an arteriovenous communication in an episcleral angioma may cause increased IOP in older patients. In many cases, however, the cause of glaucoma is obscure.
3. **Treatment** is difficult and to some extent depends on the state of the angle. Medical treatment may be tried if an angle anomaly is absent. Goniotomy may be successful in eyes with angle anomalies. Trabeculectomy may be tried in resistant cases despite the high risk of intraoperative choroidal effusion and expulsive haemorrhage.

Figure 6.132 Left buphthalmos in Sturge–Weber syndrome

NEUROFIBROMATOSIS-1

Neurofibromatosis-1 (NF-1), also known as von Recklinghausen disease, is inherited as an autosomal dominant trait with irregular penetrance and variable expressivity (*see* Chapter 15). Glaucoma is relatively rare and when present it is usually unilateral and congenital. About 50% of patients with glaucoma have an ipsilateral neurofibroma of the upper eyelid (Figure 6.133), or facial hemiatrophy.

1. **The mechanisms** of glaucoma involve one or more of the following:
   (a) Obstruction of aqueous outflow by neurofibromatous tissue in the angle.
   (b) Developmental angle anomaly which may or may not be associated with congenital ectropion uveae (Figure 6.134).
   (c) Secondary angle-closure caused by a forward displacement of the peripheral iris associated with neurofibromatous thickening of the ciliary body.
   (d) Secondary synechial angle closure caused by contraction of a fibrovascular membrane.

Figure 6.133 Plexiform neurofibroma of the eyelid in neurofibromatosis-1

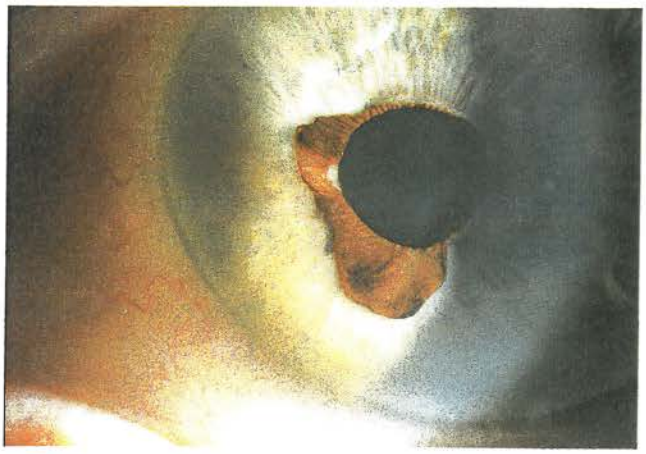

Figure 6.134 Congenital ectropion uveae in neurofibromatosis-1

2. **Treatment** is similar to that of primary congenital glaucoma but the prognosis is worse.

GLAUCOMA DRUGS

Beta-blockers

PHARMACOLOGY

Adrenergic neurones secrete noradrenaline at neuromuscular nerve endings. Adrenergic receptors are of the following three main types (Figure 6.135):

1. **Alpha-receptors** are located in the arterioles, dilator pupillae and Müller muscle. Alpha stimulation gives rise to hypertension, mydriasis, lid retraction and an increase in the facility of aqueous outflow.
2. **Beta 1-receptors** are located in heart muscle and give rise to tachycardia when stimulated.
3. **Beta 2-receptors** are located in the bronchial musculature and when stimulated give rise to bronchial dilatation.

Beta-blockers are agents that antagonize the effects of beta-agonists at beta-receptors by competing with catecholamines. They may be either ***non-selective*** or ***cardioselective***. Non-selective are equipotent at beta 1- and beta 2-receptors whereas cardioselective are more potent at beta 1- than beta 2-receptors. Currently betaxolol is the only cardioselective beta-blocker available for the treatment of glaucoma.

MODE OF ACTION

All beta-blockers reduce IOP by decreasing aqueous secretion with little effect on episcleral venous pressure, facility of outflow or uveoscleral outflow. The exact pharmacological basis for this is still unclear. About 10% of the population are, however, unresponsive. When timolol is combined with pilocarpine, a good additive effect may occur even when the latter is used only twice daily. The additive effect of sympathomimetics is poor with the possible exception of betaxolol. Beta-blockers are useful in the treatment of all types of glaucoma, irrespective of the state of the angle. In the absence of systemic contraindications they are frequently the first choice medication for POAG.

SYSTEMIC SIDE-EFFECTS

The major safety concern with the use of topical beta-blockers in the treatment of glaucoma is systemic beta-blockade caused by absorption of the drug from the nasal mucosa. Most systemic side-effects tend to occur within the first week of administration.

1. Cardiovascular side-effects such as bradycardia and hypotension can result from beta1-adrenergic blockade. However, in most patients only a small decrease in resting pulse and an insignificant reduction of

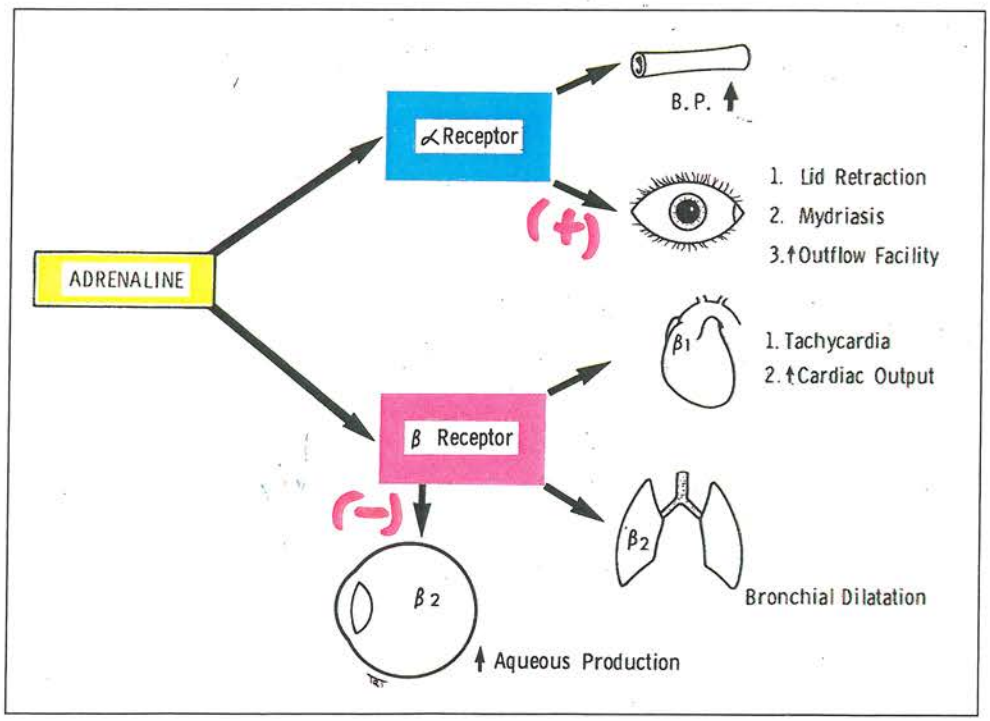

Figure 6.135 Pharmacology of adrenergic neurones

blood pressure are observed. These potential side-effects probably pose a risk only to elderly patients and those dependent on sympathetic drive to maintain cardiac output. Beta-blockers are therefore contraindicated in patients with sinus bradycardia, second-degree or third-degree heart block and cardiac failure. It is therefore important to feel the patient's pulse before prescribing a beta-blocker.

2. **Bronchospasm** may be induced by the beta 2-adrenergic blocking action. This may be fatal in patients with pre-existing asthma or severe chronic pulmonary obstruction. Patients with a past history of asthma are also at increased risk. Bronchospasm may occur with all beta-blockers but if no alternative treatment is appropriate, the cardioselective betaxolol may be tried cautiously.
3. **Miscellaneous** side-effects include: sleep disorders, hallucinations, confusion, depression, fatigue, headache, nausea, dizziness, decreased libido, skin rashes and aggravation of myasthenia gravis.
4. **Drug interactions**: because of similar pharmacological effects, concurrent use of calcium channel antagonists (e.g. verapamil, nifedipine) or quinidine with ophthalmic beta-blockers may lead to depressed atrioventricular conduction with left ventricular failure and hypotension in patients with impaired cardiovascular function.

Reduction of systemic drug absorption may be achieved by:

(a) Use of lowest concentration as infrequently as possible.
(b) Lacrimal occlusion following instillation, by closing the eyes and applying digital pressure over the lacrimal sac for about three minutes. This not only obstructs lacrimal drainage and reduces systemic absorption but also prolongs the duration of eye–drug contact and increases efficacy of the drug.
(c) Closing the eyes alone for three minutes will also reduce systemic absorption by about 50%.

PREPARATIONS

1. **Timolol** (0.25%, 0.5%) is a non-selective beta 1- and beta 2-blocker. Its onset of action is within 30 minutes, with a peak at 2 hours and a duration of up to 24 hours. Administration is twice daily. Although timolol may initially cause a dramatic fall of IOP, in some patients this effect may partially wane during the ensuing days (short-term escape). However, in most cases the drug continues to be effective for many months of therapy, although a tendency for a slow rise in IOP (long-term drift) may occur. There is probably little advantage in using the stronger concentration of the drug which is not only more expensive but appears to be no more effective than the 0.25% preparation.
2. **Timolol-LA** (0.25%, 0.5%) is a longer-acting preparation for once daily use. Its only drawback is transient blurring, which may last for up to 5 minutes.
3. **Betaxolol** (0.5%) is a relatively cardioselective beta 1-blocker and is therefore safer than timolol in patients with pulmonary disease. Its onset of action is within 30 minutes, with a peak at 2 hours and a duration of up to 12 hours. It is administered twice-daily. Although it is slightly less effective than timolol in lowering IOP its effect on preservation of the visual field appears to be superior. It has also been suggested that betaxolol increases retinal blood flow, probably by increasing perfusion pressure.
4. **Levobunolol** (0.5%) is a non-selective beta 1- and beta 2-blocker. Its onset is within 1 hour, with a peak at 2–6 hours and a duration of up to 24 hours. It is as potent as timolol in reducing IOP and usually once daily administration is adequate.
5. **Carteolol** (1%, 2%) is a non-selective beta-blocker which exhibits intrinsic sympathomimetic activity. It has a more selective action on the eye than on the cardiopulmonary system and may therefore induce less bradycardia than timolol. Its action, administration and efficacy are similar to those of timolol.
6. **Metipranolol** (0.1%, 0.3%) is a non-selective beta 1- and beta 2-blocker with properties similar to timolol.

Sympathomimetics

Sympathomimetics are alpha- and beta-adrenergic agonists which reduce IOP by increasing aqueous outflow through their beta-agonist action.

PREPARATIONS

1. **Adrenaline** (0.5%, 1%, 2%) has an onset of action within 1 hour, with a duration up to 12–24 hours and is administered twice daily. About 30% of patients with POAG are unresponsive to adrenaline and local side-effects, such as irritation and conjunctival injection, are common. With long-term use innocuous, black, conjunctival adrenochrome deposits (Figure 6.136) may develop. The 2% concentration should be avoided in aphakic patients because of the possibility of causing cystoid macular oedema. Adrenaline should also be avoided in patients with occludable angle because the mydriasis caused by the drug may precipitate angle-closure glaucoma.
2. **Dipivefrin** (0.1%) is a pro-drug which is converted to adrenaline after its absorption into the eye. Its corneal penetration is 17 times better than that of adrenaline. Its duration of action and administration are the same as of adrenaline. The ocular hypotensive effect of dipivefrin 0.1% is comparable to 1% adrenaline. Dipivefrin causes fewer local side effects so that

Figure 6.136 Conjunctival adrenochrome deposits

patients intolerant to adrenaline may be able to use dipivefrin.

3. **Brimonidine** (0.2%) is a selective alpha 2-adrenergic agonist which has a peak effect at 2 hours, with a duration of 12 hours and is administered twice daily. It lowers IOP by decreasing aqueous production and enhancing uveoscleral outflow. The ocular hypotensive effect is comparable to timolol and it has an additive effect to beta-blockers. The only systemic side effects are mild drowsiness and a slight reduction in blood pressure which is usually clinically insignificant. In some patients it may cause ocular irritation.
4. **Apraclonidine** (0.5%, 1%) is an alpha 2-adrenergic agonist which is most commonly used to reduce the risk of rise in IOP following laser trabeculoplasty and YAG laser iridotomy. It is of limited use for long-term administration because of the high rate of ocular side-effects.

Miotics

MODE OF ACTION

1. **In primary open-angle glaucoma** cholinergic stimulators reduce IOP by increasing aqueous outflow by the following postulated mechanism: the drug contracts the longitudinal muscle of the ciliary body thereby exerting a pull on the scleral spur and producing changes in the trabecular meshwork, which enhance aqueous outflow. Miotics are very effective in lowering IOP in open-angle glaucomas and have a good additive action when combined with other anti-glaucoma drugs. When pilocarpine is used in combination with a beta-blocker a good additive effect may occur with only twice daily administration.
2. **In primary angle-closure glaucoma** cholinergic stimulators reduce IOP by opening the angle which results from the mechanical contraction of the pupil pulling the peripheral iris away from the trabeculum.

LOCAL SIDE-EFFECTS

Local side-effects (Figure 6.137) are a significant problem and are mainly responsible for low compliance on these medications.

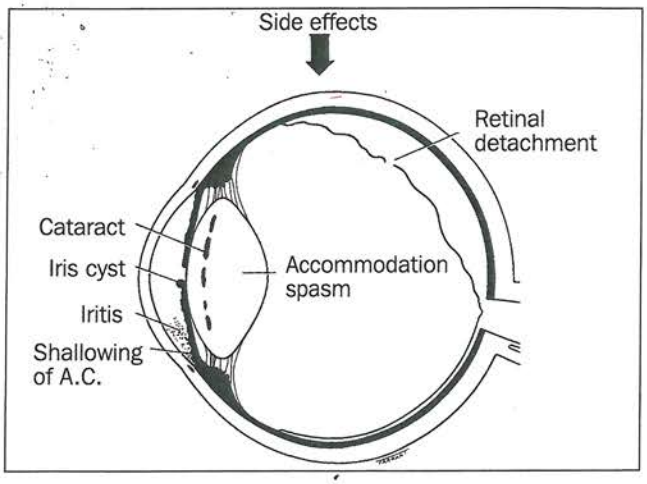

Figure 6.137 Local side-effects of miotics

1. **Miosis** may cause the following problems:
   (a) Impairment of night vision.
   (b) Reduced visual acuity in the presence of axial lens opacities.
   (c) Generalized constriction of the visual field.
   (d) Apparent increase in the size of visual field defects.
   (e) Permanent miosis.
2. **Spasm of accommodation** may cause the following effects:
   (a) Myopia may be a considerable problem in young patients. Because the degree of induced myopia is variable, it cannot always be overcome by spectacles.
   (b) Frontal headache is a frequent problem at the start of miotic therapy, but it usually regresses after a week or two. If severe, it can usually be relieved with salicylates.
3. **Retinal detachment** is a very rare complication which should be suspected if the glaucomatous eye suddenly develops a dramatic drop in IOP or vision. Ideally, the fundus should be examined and any predisposing retinal lesions treated prophylactically prior to starting miotic therapy.
4. **Angle-closure glaucoma** may be precipitated in eyes with narrow angles due to a combination of shallowing of the anterior chamber as a result of forward movement of the iris–lens diaphragm and an increase in the anteroposterior diameter of the lens caused by contraction of the ciliary muscle.

PREPARATIONS

1. **Pilocarpine** (1%, 2%, 3%, 4%) is a parasympathomimetic muscarinic agonist. The onset of action is within 20 minutes, with a peak at two hours and a duration up to six hours. Because of the relatively short duration of action the drug has to be administered four times daily when used alone, although when used in combination with a beta-blocker, twice-daily administration may be adequate. In the treatment of POAG pilocarpine is at least as potent as beta-blockers and more effective than sympathomimetics. Concentrations above 4% may have a slightly more prolonged effect but no further reduction of IOP.
2. **Pilocarpine gel** consists of pilocarpine 4% adsorbed on to a plastic gel which is applied once at bedtime so that the induced myopia and miosis last only during sleep. The main disadvantage is the development of a diffuse superficial corneal haze in 20% of users, although this rarely affects visual acuity.
3. **Pilocarpine sustained-release** (Ocusert Pilo-20 and Pilo-40) is a polymer containing adsorbed pilocarpine which is released at a steady rate. The membrane, which is similar to a soft contact lens, is inserted into the upper fornix and left in situ for seven days. The efficacy of Pilo-20 is equivalent to pilocarpine 1% drops and Pilo-40 is equivanent to pilocarpine 2–4%.
4. **Carbachol** (3%) is a parasympathomimetic muscarinic agonist and also a weak cholinesterase inhibitor. Its onset of action is within 40 minutes with a duration up to 12 hours. Because of this relatively long duration the drug is used three times daily (i.e. 8-hourly). Carbachol is a very good alternative to pilocarpine in resistant or intolerant cases.

Prostaglandin derivatives

Latanoprost is a new prostaglandin F2-alpha analogue with a hypotensive effect similar to timolol. The mode of action is different from other drugs as it enhances uveoscleral outflow without altering aqueous flow through the trabeculum. Its pressure lowering effect is therefore additive to most other medications. It has a duration of action of 24 hours and is administered once daily, preferably in the evening. Local side-effects consisting mainly of a foreign body sensation and mild conjunctival hyperaemia occur in about 10% of patients. It may also cause increased pigmentation of the iris in a small percentage of patients (Figure 6.138).

Figure 6.138 Hyperpigmentation of the right iris due to unilateral use of latanoprost

Carbonic anhydrase inhibitors

PHARMACOLOGY

The carbonic anhydrase inhibitors (CAIs) are agents which are chemically derived from sulphonamides. They lower IOP by reducing aqueous secretion through direct inhibition of the enzyme carbonic anhydrase and to a lesser extent by inducing an acidosis. Systemically administered, CAIs are useful as short-term treatment of acute glaucomas but their long-term use is usually reserved for patients with a high risk of visual loss. Additive effects are very good when combined with miotics.

SYSTEMIC SIDE-EFFECTS

The usefulness of systemic CAIs in long-term therapy is often limited by their side-effects (Figure 6.139).

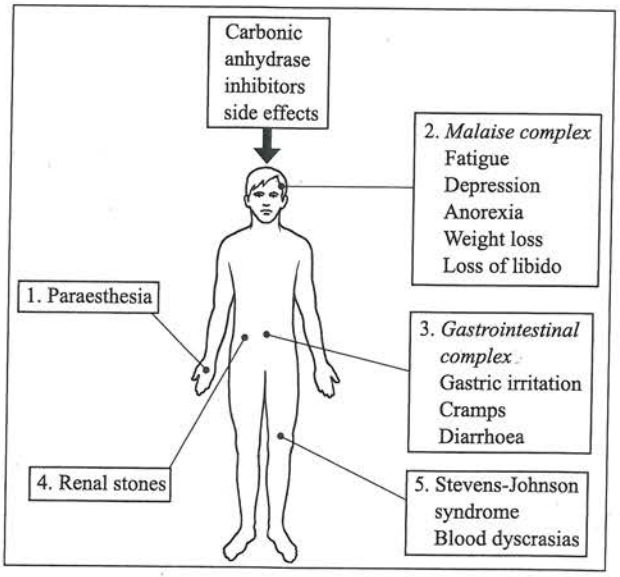

Figure 6.139 Systemic side-effects of carbonic anhydrase inhibitors

Compliance is poor and only about one-third of patients take their medication regularly. In most cases the severity of side-effects is dose-related and it can be reduced by decreasing the dose, changing to another preparation or using a sustained-release preparation. The patient should always be warned of potential side-effects as this decreases anxiety and improves compliance.

1. **Paraesthesiae** characterized by tingling of the fingers, toes, hands or feet, and occasionally at the mucocutaneous junctions, is a universal finding and is usually innocuous. Compliance should be questioned if the patient denies this symptom.
2. **The malaise symptom complex** is characterized by a combination of malaise, fatigue, depression, weight loss and decreased libido. This is associated with excessive serum levels and drug-induced metabolic acidosis. A supplemental two-week course of sodium acetate may be helpful in many cases.
3. **The gastrointestinal symptom complex** is characterized by gastric irritation, abdominal cramps, diarrhoea and nausea. This can occur independently of the malaise syndrome and it is unrelated to any specific changes in blood chemistry.
4. **Renal stone formation** is rare and is related to a decrease in the urinary excretion of citrate without a corresponding fall in serum calcium.
5. **Stevens–Johnson syndrome**, although very rare, may occur because CAIs are sulphonamide derivatives.
6. **Blood dyscrasias** are extremely rare and are of two types:
   (a) A dose-related bone-marrow suppression which usually recovers when treatment is stopped.
   (b) An idiosyncratic aplastic anaemia which is not dose-related and has a mortality of 50%. It can occur after only one dose but it usually develops during the first two to three months and very rarely after six months administration.
7. **Drug interactions**
   (a) Thiazide diuretics may potentiate hypokalaemia.
   (b) Steroids may also potentiate hypokalaemia.
   (c) Salicylates may potentiate metabolic acidosis.
   It is therefore very important to enquire about other systemic drugs before prescribing CAIs.

SYSTEMIC PREPARATIONS

1. **Acetazolamide tablets** 250 mg. The dose is 250–1000 mg in divided doses. The onset of action is within 1 hour, with a peak at 4 hours and a duration up to 12 hours.
2. **Acetazolamide sustained-release capsules** 250 mg. The dose is 250–500 mg daily with a duration of up to 24 hours.
3. **Acetazolamide powder** 500 mg vials for injection. The onset of action is almost immediate, with a peak at 30 minutes and a duration of up to 4 hours. This is the only CAI preparation available for injection and is useful in the treatment of acute angle-closure glaucoma.
4. **Dichlorphenamide tablets** 50 mg. The dose is 50–100 mg (2–3 times daily). The onset of action is within 1 hour, with a peak at 3 hours and a duration of up to 12 hours.
5. **Methazolamide tablets** 50 mg. The dose is 50–100 mg (2–3 times daily). The onset of action is within 3 hours, with a peak at 6 hours and a duration of up to 10–18 hours. This is a useful alternative to acetazolamide with a longer duration of action but is currently not available in the United Kingdom.

TOPICAL PREPARATIONS

The only currently available topical CAI is dorzolamide (2%). It is administered three times daily as monotherapy and twice daily when used in combination with another drug. Its peak activity is at 2 hours. It is as effective as betaxolol in reducing IOP but not as effective as timolol, with a mean IOP decrease of about 15%. Although well tolerated, some patients experience a bitter taste or with long-term administration develop local adverse effects such as conjunctivitis or lid reactions which resolve on discontinuation of therapy.

Hyperosmotic agents

PHYSIOLOGICAL PRINCIPLES

The osmotic pressure is dependent on the number and not on the size of particles in solution. For this reason, the smaller the molecular weight, the greater the effect per gram in osmotic therapy. Hyperosmotic agents lower IOP by increasing blood osmolality thereby creating an osmotic gradient between blood and vitreous so that water is drawn from the vitreous. The higher the gradient the greater the reduction of IOP. To be effective a hyperosmotic agent must be unable to penetrate the blood–aqueous barrier. If penetration occurs, an equilibrium is set up and any further effect is lost. Hyperosmotic agents are therefore of limited value in the treatment of inflammatory glaucomas in which the blood–aqueous barrier is not intact.

CLINICAL USES

Hyperosmotic agents are extremely useful when a temporary drop in IOP is required that cannot be obtained by other means. This applies particularly to patients with acute angle-closure glaucoma. They are also useful prior to intraocular surgery when the IOP is very high, as may occur from dislocation of the lens into the anterior chamber. These preparations should be given fairly rapidly and the patient should not subsequently be given fluids to quench thirst.

SIDE-EFFECTS

1. **Cardiovascular overload** may occur as a result of increased extracellular volume following intravenous administration. Hyperosmotic agents should therefore be used with great caution in patients with cardiac or renal disease.
2. **Urinary retention** may occur in elderly men following intravenous administration. A Foley catheter should therefore be inserted in those with 'prostatism'.
3. **Miscellaneous** side-effects include: headache, backache, nausea and mental confusion.

PREPARATIONS

1. **Glycerol** is an oral agent with a sweet and sickly taste. Pure lemon (not orange) juice has to be added to avoid nausea. The dose is 1–2 g/kg body weight or 2–4 ml/kg body weight (50% solution) (Figure 6.140, **left**). The peak of action is within 1 hour, with a duration up to 3 hours. Although glycerol is metabolized to glucose in the body, it can be given to diabetics provided they are well controlled.
2. **Isosorbide** is also an oral agent, with a minty taste. It is metabolically inert and can therefore be given to diabetics without insulin cover. The dose is the same as for glycerol (Figure 6.140, **right**).
3. **Mannitol** is the most widely used intravenous hyperosmotic agent. The dose is 1–2 g/kg body weight or 5 ml/kg body weight (20% solution in water). The speed of administration via a drip should not exceed ≤ 60 drops/min over 20–30 minutes. The peak of action is reached within 30 minutes, with a duration of up to 6 hours.

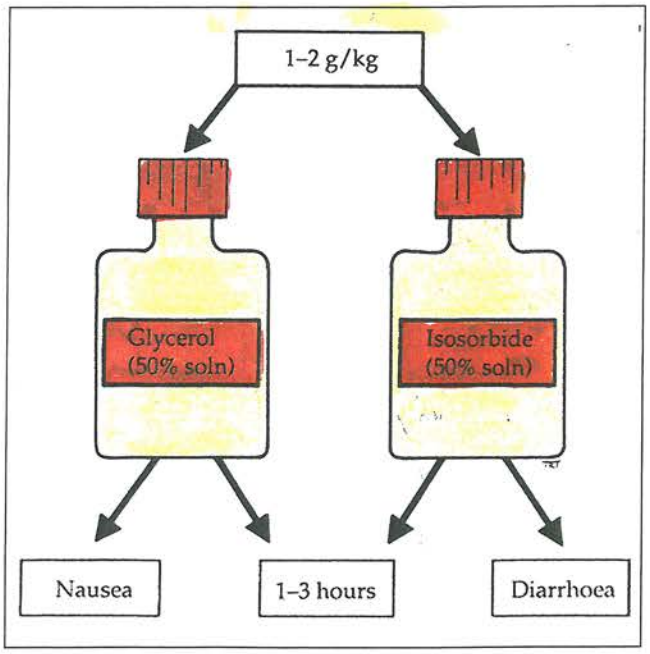

Figure 6.140 Oral hyperosmotic agents

LASERS IN GLAUCOMA

Introduction

Laser trabeculoplasty (LT) is a procedure by which the application of discrete laser burns to the trabeculum enhances aqueous outflow and lowers IOP. Laser therapy can be performed with either the argon or diode laser. The main indications in POAG have already been discussed. The procedure is contraindicated in the following circumstances:

1. **Where the trabeculum is not visible.**
2. **When it is ineffective**, such as paediatric glaucomas and most secondary glaucomas with the exception of pigmentary glaucoma and pseudoexfoliation glaucoma.
3. **Following previous failed 360° LT.**

Argon laser trabeculoplasty

TECHNIQUE

1. Instil a drop of apraclonidine 1% (Iopidine) to prevent early post-LT rise in IOP.
2. Use blue–green laser energy with the following settings: (a) spot size 50 μm; (b) duration 0.1 sec; (c) initial power of 700 mW.
3. Instil two drops of a topical anaesthetic and insert a clean goniolens with antireflective coating.
4. With the mirror at 12 o'clock view the inferior angle (usually the easiest part to see).
5. Identify the scleral spur and Schwalbe line (which may be pigmented) and the three-dimensional ground-glass appearance of the trabeculum.
6. Focus the aiming beam at the junction of the pigmented and non-pigmented trabeculum.
7. Make sure that the spot is round and has a clear edge (Figure 6.141**a**). An oval spot with a blurred outline (Figure 6.141**b**) means that the aiming beam is not perpendicular to the surface of the goniolens.
8. Fire the laser. The ideal reaction is a transient blanching (Figure 6.142**a**) or the appearance of a minute gas bubble at the point of impact (Figure 6.142**b**).
9. If the reaction is inadequate, increase the power by 200 mW steps up to 1200 mW. In heavily pigmented angles, a power setting of as little as 400 mW may suffice, whereas some non-pigmented angles may require up to 1200 mW (average is about 900 mW).

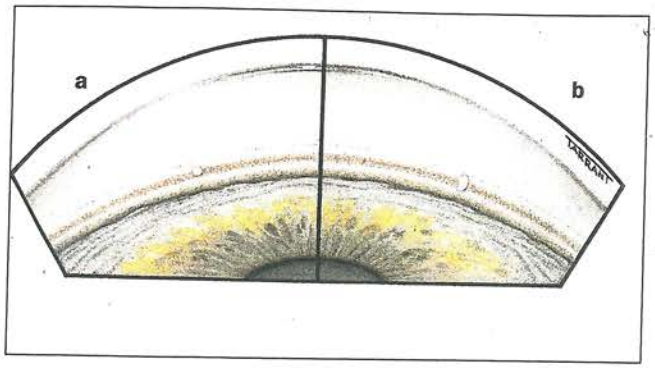

Figure 6.141 Laser trabeculoplasty. **a**: correct focus with round aiming beam; **b**: incorrect focus with oval aiming beam

10. Apply 25 burns at regularly spaced intervals from one end of the mirror to the other.
11. Rotate the goniolens clockwise for 90° and apply a further 25 burns making a total of 50 extending for 180° of the angle. It is important to be familiar with the rotational pattern of the mirror so that adjacent quadrants are treated systematically. With practice it is possible to perform LT by continuously rotating the goniolens and applying each burn through the centre of the mirror. Some initially treat only 180° and go on to treat the other 180° if the response is unsatisfactory. Others, however, treat the entire circumference with 100 burns at the initial sitting.
12. Instil one drop of apraclonidine 1%.
13. Send the patient home on weak topical steroid drops (i.e. fluorometholone or clobetasone) four times daily for one week and continue all antiglaucoma medication.

SIX WEEK FOLLOW-UP

1. If the IOP is satisfactory try to reduce glaucoma medication gradually, although total withdrawal is rarely possible. For example, it may be possible to discontinue systemic carbonic anhydrase inhibitors although topical therapy may still be required. The main aim of LT is to obtain a safe IOP and the reduction of medication is usually a secondary consideration.
2. If IOP is still high and only 180° has been treated, complete the LT for 360°. Following 360° LT, re-treatment is unlikely to be beneficial and filtration surgery may have to be considered.
3. Check visual fields at 3 months.

COMPLICATIONS

1. **Peripheral anterior synechiae** may develop if the burns are applied too posteriorly (Figure 6.142**d**) or if the energy level is high (Figure 6.142**c**). In the majority of cases this does not result in a reduction of aqueous outflow.
2. **Small haemorrhages** may develop if the blood vessels on the peripheral iris or ciliary body are inadvertently treated. The bleeding is easily stopped by applying pressure on the globe with the goniolens.
3. **Acute elevation of IOP** occurs in about 25% of patients if prophylactic apraclonidine is not used.
4. **Anterior uveitis** is fairly common but is usually mild, transient and innocuous.
5. **Adverse effect of subsequent filtration surgery**. The incidence of encapsulated blebs following filtration surgery is up to three times higher in eyes previously treated with LT.

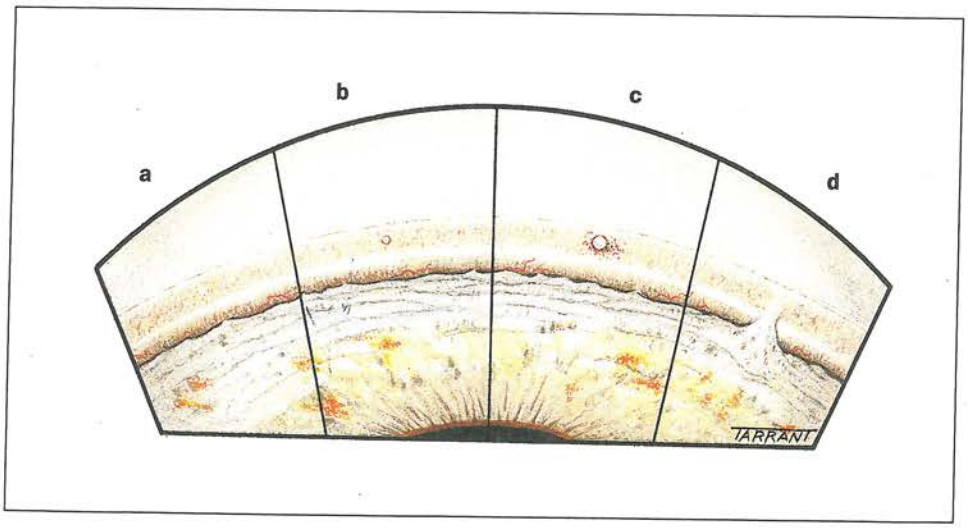

Figure 6.142 Laser trabeculoplasty. (**a**) Blanching of trabeculum – correct reaction; (**b**) small bubble – also correct reaction; (**c**) large bubble – excessive reaction; (**d**) peripheral anterior synechiae caused by applying the burn too posteriorly

RESULTS

1. **In POAG** the initial success rate is 75–85%. The average reduction of IOP is 30% or less so that eyes with initially high IOPs will have a greater reduction of IOP than those with lower IOPs. In general, up to 50% of eyes are still controlled after five years and about 33% after ten years. Because failure occurs most frequently in the first year, if the IOP is still controlled at one year, the probability of control after five years is 65% and after ten years, about 40%. If LT is used as primary treatment, 50% of cases require additional medical therapy within two years. Following initially successful LT, re-treatment can be considered but the success rate is low (30% after one year and only 15% after two years). In general the results are less good in patients under the age of 50 years. In black patients the initial results are as good as in whites but blacks tend to have a more rapid loss of effect.
2. **In normal-tension glaucoma** between 50 and 70% of patients have a good response, but the actual reduction in IOP is less than that in POAG.
3. **In pigmentary glaucoma** the results are generally good although the reduction of IOP in older patients may be less than in younger individuals.
4. **In pseudoexfoliation glaucoma** the initial results are excellent, although failure may occur earlier than in POAG and the rise in IOP may occur rapidly.

Diode laser trabeculoplasty

Diode laser trabeculoplasty gives similar results to argon laser trabeculoplasty, although it is associated with less disruption of the blood–aqueous barrier. The following are the main practical differences between the two modes:

1. A higher laser power of between 800 and 1200 mW has to be used.
2. The burns are less intense than with argon laser trabeculoplasty and although blanching is observed bubble formation does not occur.
3. The spot size is 100 µm although it can be diminished by the use of a special contact lens by a factor of 30% resulting in a spot size of 70 µm.
4. The pulse duration can be either 0.1 or 0.2 seconds.

Nd:YAG laser iridotomy

INDICATIONS

1. Primary angle-closure glaucoma – acute, intermittent and chronic.
2. Fellow eye of patients who present with acute glaucoma.
3. Narrow 'occludable' angles.
4. Secondary angle closure with pupil block.
5. POAG with narrow angles and 'combined mechanism' glaucoma.

TECHNIQUE

1. Instil apraclonidine 1%, and ensure that the pupil is miosed as much as possible although this may not be possible following acute glaucoma.
2. Laser settings vary according to the machine used. The majority of iridotomies are made with settings between 4 and 8 millijoules (mJ). When penetrating a thin blue iris the energy level is approximately 1–4 mJ per shot, with two to three shots per burst. The energy level has to be increased by 50–100% when penetrating a thick, velvety smooth, brown iris. This can be achieved either by using more power or more shots per burst. Although with a higher energy level and more shots per burst it is easier to penetrate the iris with fewer bursts, it is associated with an increased risk of intraocular damage. As a general guideline three bursts of 3–6 mJ is usually effective.
3. Insert a special 'converging' contact lens such as the Abraham (Figure 6.143).

Figure 6.143 Abraham lens used for laser iridotomy

4. Select an iridotomy site which should be in a superior quadrant so that it is covered by the eyelid. The iridotomy should also be as peripheral as possible but inside an arcus senilis to ensure that any excess laser energy which penetrates the iris is less likely to damage the lens. Finding an iris crypt is not essential.
5. Angle the beam so that it is non-perpendicular and aimed towards the peripheral retina to avoid the remote possibility of a macular burn. Because of the wide incident beam make sure that the incident light is not being interrupted by the edge of the contact lens.
6. Precisely focus the beam and penetrate the iris. Successful penetration is characterized by a gush of

pigment debris. On average seven shots are required to produce an adequate iridotomy although with practice this can be reduced to one or two.
7. Instil one drop of apraclonidine 1%.
8. Prescribe a topical steroid every 5 minutes for 30 minutes after treatment and then hourly for 6 hours. Subsequent administration is four times daily for five days.

POTENTIAL TECHNICAL PROBLEMS

1. **Initial failure** is managed either by re-treating at the same site or by moving to a different site and increasing the energy level. The decision to re-treat at the same site depends in part on the degree of pigment dispersion and haemorrhage caused by the previous partial treatment. In thick brown irides an incomplete treatment may result in a thick cloud of dispersed iris pigment which impairs visualization and accurate focusing on the base of the crater. Further applications applied into the cloud may merely increase the amount of pigment and haemorrhage and still not produce an opening. In this situation it is best either to wait for the cloud to disperse and then re-treat at the same site with a lower energy level, or to increase the energy level and try at a different site.
2. **Opening too small**: the ideal diameter is 150–200 μm (Figure 6.144) If the opening is too small it is sometimes easier to create an additional opening at a different site rather than to try to enlarge the opening.

COMPLICATIONS

1. **Bleeding** occurs in about 50% of cases. It is usually slight and stops after several seconds. Persistent bleeding can be terminated by pressing the contact lens against the cornea. This complication is significantly less common when apraclonidine 1% is used.
2. **Iritis** is common and usually mild. Severe iritis, which may result in the formation of posterior synechiae (Figure 6.145), is invariably caused by overtreatment and failure to prescribe adequate postoperative steroids.
3. **Corneal burns** may occur if a contact lens is not used or if the iridectomy is performed in an eye with a shallow anterior chamber.
4. **Glare and diplopia** may rarely occur if the iridotomy is not placed under the upper eyelid.

Figure 6.144 Appearance following Nd:YAG laser iridotomy with the correct size opening in the iris

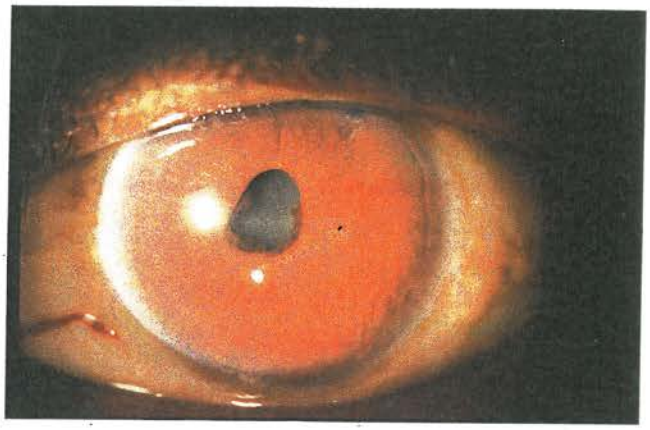

Figure 6.145 Posterior synechiae as a complication of Nd:YAG laser iridotomy

TRABECULECTOMY

Introduction

DEFINITION

A conventional filtering (drainage) procedure lowers IOP by creating a new channel (fistula) for aqueous outflow between the anterior chamber and sub-Tenon space without the use of an artificial device. The following are the two main types:

1. **Partial-thickness** (trabeculectomy), in which the fistula is protected or 'guarded' by a superficial scleral flap (Figure 6.146**a**). It has a lower rate of postoperative complications but the long-term failure rate is slightly greater than with full-thickness procedures.
2. **Full-thickness** (Scheie thermosclerostomy, trephine and posterior lip sclerectomy) in which the fistula passes through the entire thickness of the sclera (Figure 6.146**b**). They are now seldom performed and will not be discussed further.

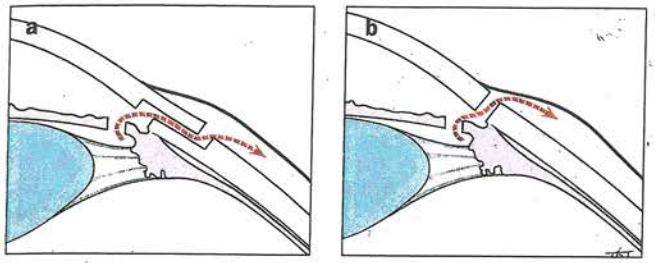

Figure 6.146 Filtration procedures. **a**: partial-thickness (trabeculectomy); **b**: full-thickness

INDICATIONS

In most cases, the indication for trabeculectomy is a patient with glaucoma on maximum tolerated medical therapy who has had laser trabeculoplasty and whose optic nerve function is failing or is considered likely to fail. There is, however, a modern school of thought that recommends early surgery in patients with uncontrolled IOP on topical therapy alone. The success rate of trabeculectomy in POAG and pseudoexfoliation glaucoma is between 90 and 95%.

Surgical technique

1. **The conjunctival flap** can be either limbal-based (Figures 6.147, 6.148 and 6.149) or fornix-based (Figure 6.150).

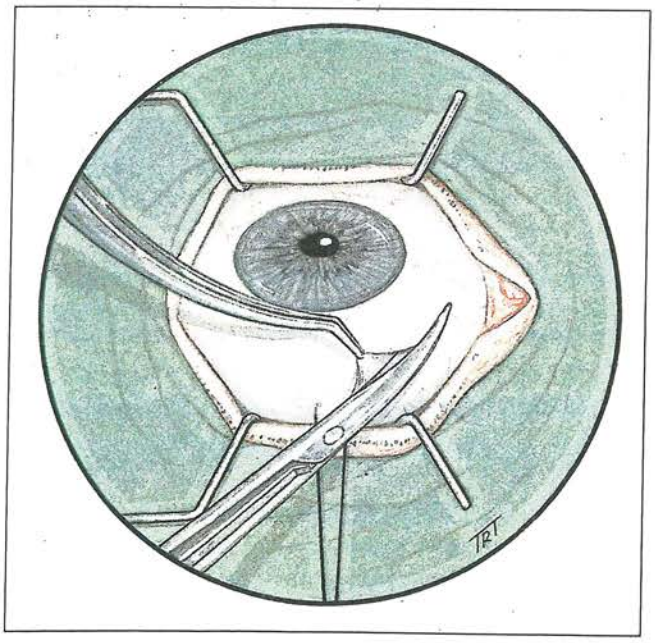

Figure 6.147 Initial conjunctival incision for a limbal-based flap

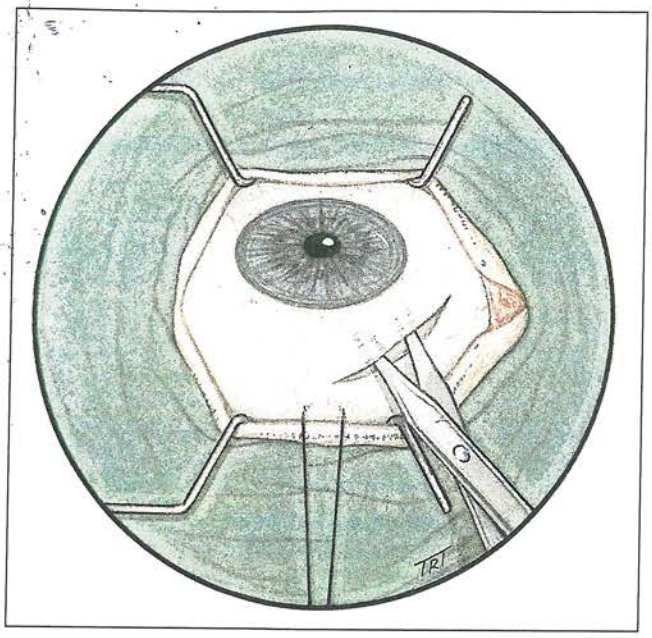

Figure 6.148 Undermining of conjunctiva

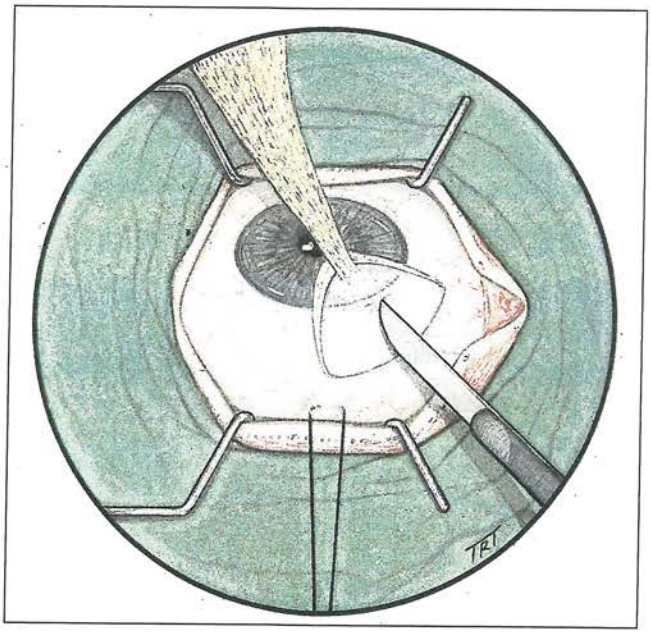

Figure 6.149 Clearing of the limbus

2. **Outline of the superficial scleral flap** is made with wet-field cautery and then incisions are made along the cautery marks through two-thirds of scleral thickness (Figure 6.151). The flap may be rectangular (3 × 4 mm), square or triangular, according to preference.
3. **Dissection of the superficial scleral flap** is then made by keeping the blade flat against the sclera and continuing to dissect anteriorly (Figure 6.152) in the same plane until clear cornea has been reached

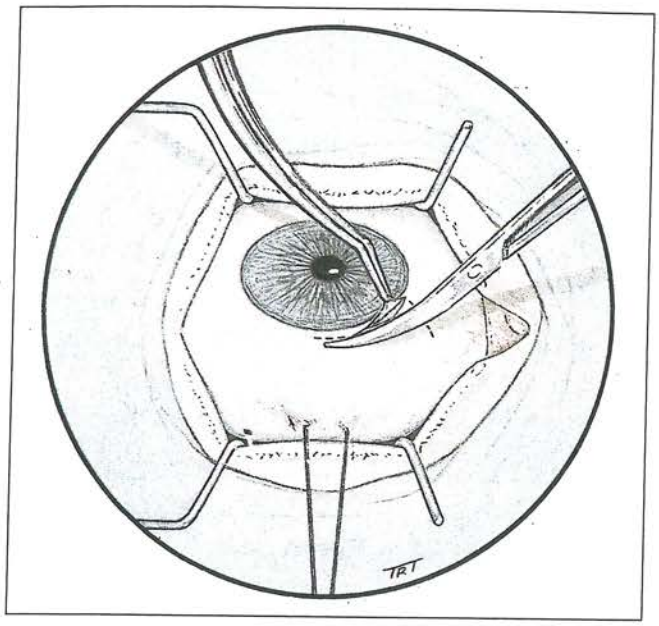

Figure 6.150 Limbal conjunctival incision for a fornix-based conjunctival flap

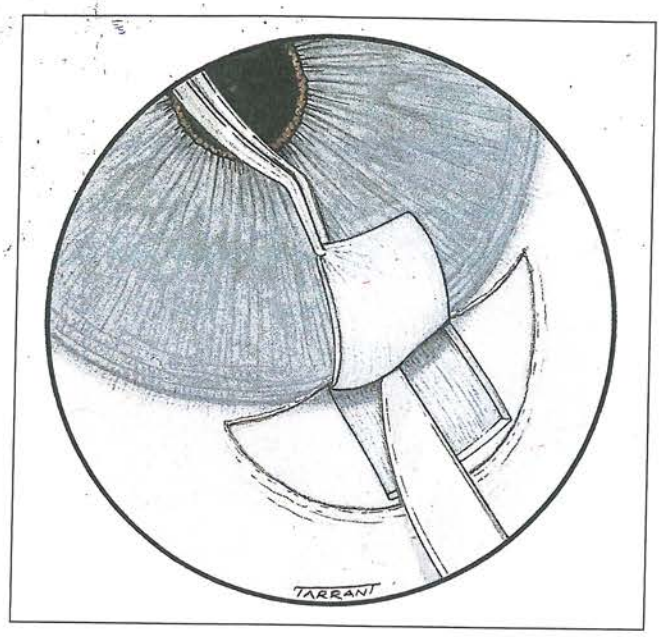

Figure 6.152 Dissection of the superficial scleral flap

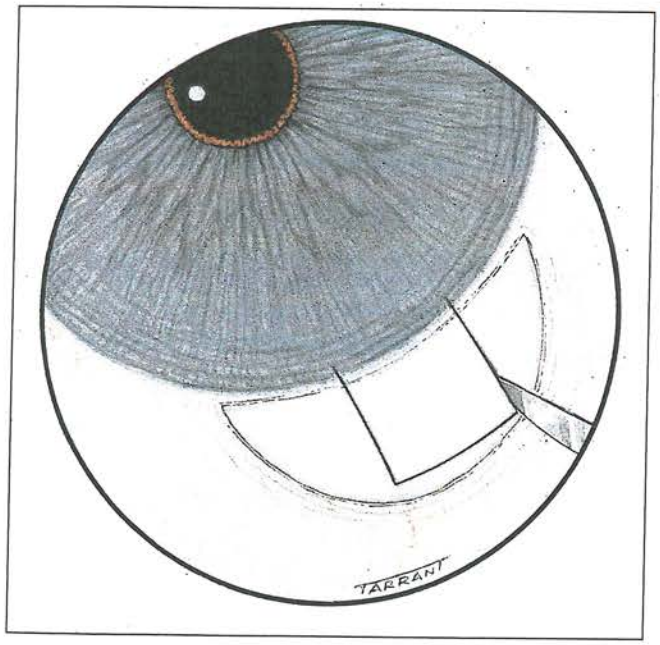

Figure 6.151 Outline of superficial scleral flap



Figure 6.153 Excised deep block of tissue during trabeculectomy

4. **A paracentesis** is performed with a thin-bladed knife, placing the incision in upper temporal peripheral clear cornea.
5. **The deep sclerectomy** is the most difficult part of the operation. It involves the excision of a deep rectangular block (1.5 × 3 mm) which may contain scleral spur, Schlemm canal, trabeculum, Schwalbe line and peripheral cornea (Figure 6.153). It can be performed either with a knife and scissors (Figures 6.154 and 6.155), or with a special (Kelly) punch (Figure 6.156).
6. **A peripheral iridectomy** (Figure 6.157) is performed to prevent blockage of the internal opening by the peripheral iris.
7. **The superficial flap** is sutured and balanced salt solution is injected into the anterior chamber through the paracentesis with a Rycroft cannula (Figure 6.158**a**). This tests the patency of the fistula and facilitates the detection of any holes or leaks.
8. **The conjunctiva is closed** (Figure 6.158**b**).

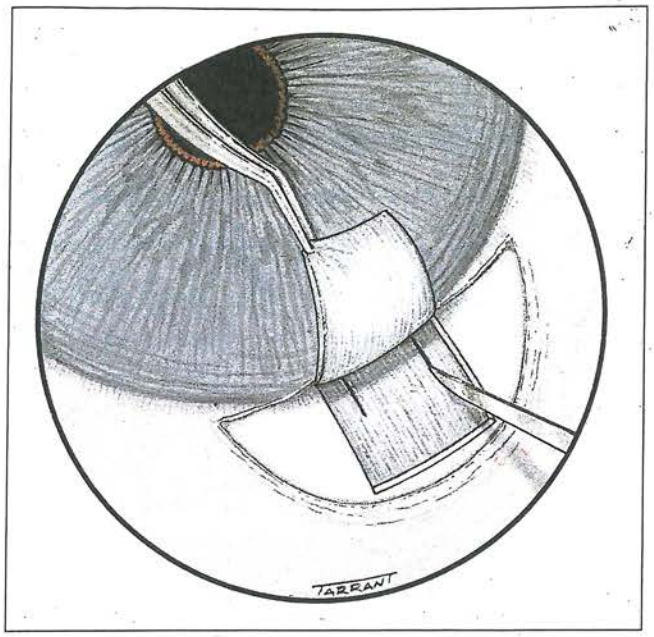

Figure 6.154 Incisions for sclerectomy

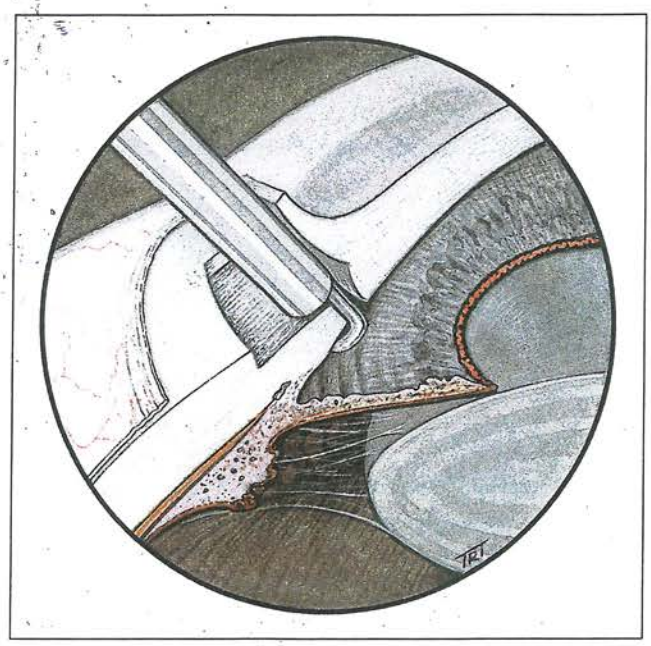

Figure 6.156 Kelly punch technique for excision of deep block

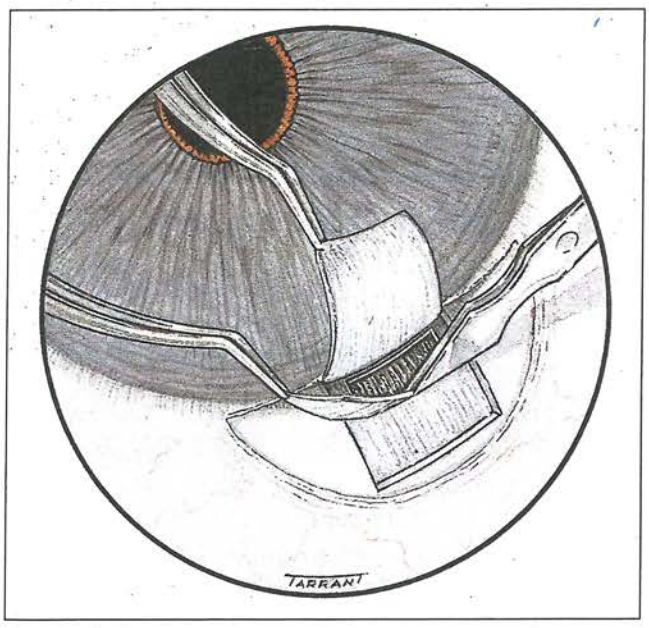

Figure 6.155 Excision of the deep block with Vannas scissors

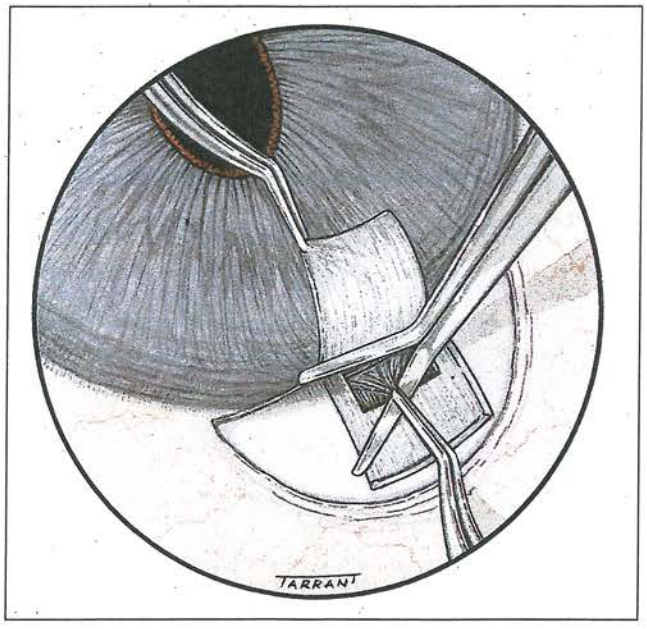

Figure 6.157 Peripheral iridectomy

Postoperative complications

SHALLOW ANTERIOR CHAMBER

Severe and sustained shallowing of the anterior chamber is rare (Figure 6.159). Although the chamber re-forms spontaneously in most cases, those that do not result in severe complications such as peripheral anterior synechiae, corneal endothelial damage (Figure 6.160), cataract (Figure 6.161) and hypotony-associated maculopathy (Figure 6.162). The following are the main causes of a shallow anterior chamber: (a) ***wound leak***, (b) ***excessive filtration***, (c) ***pupillary block*** and (d) ***malignant glaucoma***. The clinical evaluation of an eye with a shallow anterior chamber is as follows:

1. Measure the IOP.
2. Assess the state of the filtering bleb.
3. Confirm patency of the peripheral iridectomy to rule out pupil block.

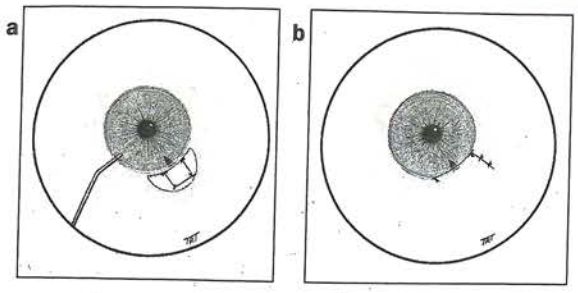

Figure 6.158 a: injection of balanced salt solution into the anterior chamber; **b**: appearance following suturing of a fornix-based flap

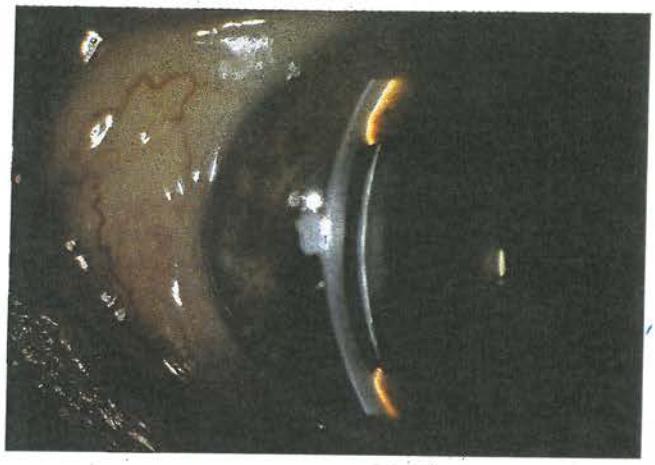

Figure 6.159 Shallow anterior chamber following trabeculectomy

Figure 6.160 Corneal oedema resulting from lenticulo-corneal touch following trabeculectomy

4. Perform the Seidel test by instilling fluorescein into the superior fornix and observing the bleb with a cobalt blue filter; if a leak is present the fluorescein will become diluted by aqueous (Figure 6.163).
5. Examine the fundus for the presence of a choroidal detachment (Figure 6.164).

Figure 6.161 Anterior lens opacities following inappropriate management of a flat anterior chamber

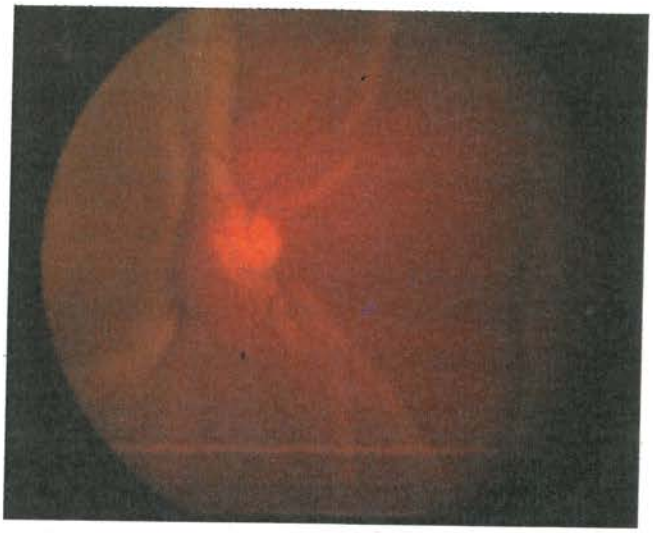

Figure 6.162 Extensive chorioretinal folds in an eye with severe hypotony

Figure 6.163 Positive Seidel test

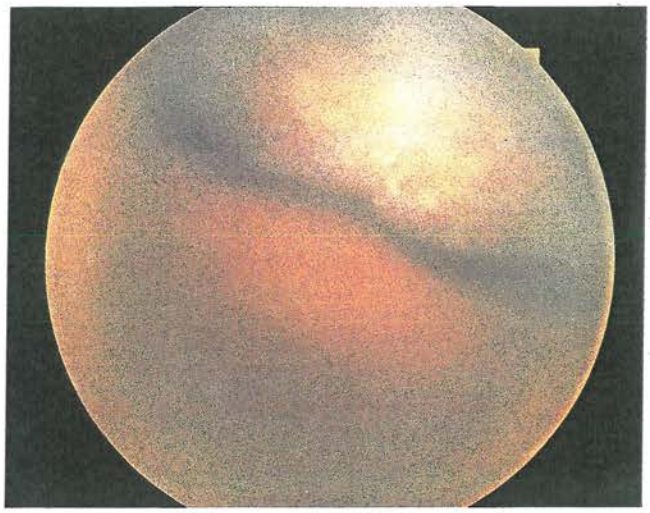

Figure 6.164 Choroidal detachment in a hypotonous eye following trabeculectomy

1. **Wound leak**
   (a) ***Signs*** – low IOP, a poor bleb and a positive Seidel test.
   (b) ***Management***
   - Stop all topical medication.
   - Dilate the pupil.
   - Apply a pressure dressing or a large diameter soft contact lens. Provided the leak is small it should settle spontaneously within 24–48 hours.
   - Consider the use of oral acetazolamide for 24–48 hours.
   - If a large leak is present the conjunctiva may require additional sutures.
2. **Excessive filtration**
   (a) ***Signs*** – low IOP, good bleb, negative Seidel test and frequently choroidal detachments.
   (b) ***Management***
   - Keep the pupil well dilated with atropine 1% drops.
   - Instil topical steroids to reduce the amount of associated inflammation so as to reduce the risk of formation of peripheral anterior synechiae. In most cases the anterior chamber will re-form and the choroidal detachment will flatten spontaneously.
   - Scleral shell tamponade using a 'Simmons shell' may be useful.
   - Aqueous suppressants can also be used.
   - If the shallowing is increasing and there is danger of lenticulocorneal touch, reform the anterior chamber surgically as follows: drain the choroidal detachment by making a scleral incision where the detachment is deepest and reform the chamber with air. Balanced salt solution and hyaluronic acid are not as effective because they fairly rapidly pass through the fistula.
3. **Pupillary block**
   (a) ***Signs*** – high IOP, flat bleb and a non-patent iridectomy.
   (b) ***Management***
   - Complete the iridectomy with a Nd:YAG laser or perform a new iridotomy.
   - Dilate the pupil with atropine 1% and phenylephrine 10%.
4. **Malignant glaucoma** (ciliary block glaucoma) is a rare but potentially very serious complication which is caused by blockage of aqueous flow at the secreting portion of the ciliary body, so that the aqueous is forced backwards into the vitreous.
   (a) ***Signs*** – increased shallowing of the anterior chamber usually evolving during the first few days, high IOP, no bleb and a negative Seidel test.
   (b) ***Management***
   - Topical therapy with mydriatics (atropine 1% and phenylephrine 10%) is used to dilate the ciliary ring in order to increase the distance between the ciliary processes and the equator of the lens, thereby tightening the zonule and pulling the lens posteriorly into its normal position.
   - Systemic therapy with intravenous mannitol is used if mydriatics are ineffective in order to shrink the vitreous gel and allow the lens to move posteriorly.
   - Nd:YAG laser may be used if medical therapy fails. The laser is fired through the iridectomy in order to disrupt the anterior hyaloid face and break the ciliary block.
   - Posterior vitrectomy is performed if laser therapy fails. A pars plana incision is used and sufficient vitreous gel excised with the cutter to allow free flow of aqueous to the anterior chamber. If a vitreous cutter is not available the entrapped fluid can be aspirated with a 20-gauge needle inserted 3 mm posterior to the limbus and directed towards the centre of the globe.

LATE BACTERIAL INFECTION

1. **Risk factors**: the thin-walled cystic bleb (Figure 6.165) with a positive Seidel test, particularly if associated with the use of adjunctive antimetabolite therapy, is a significant risk because it drains transconjunctivally and is, therefore, most likely to provide a pathway for the entry of bacteria into the eye. All patients with this type of bleb should be warned of the possibility of late infection and strongly advised to report immediately if they develop a red and sticky eye, or blurred vision.

Figure 6.165 Thin polycystic filtration bleb

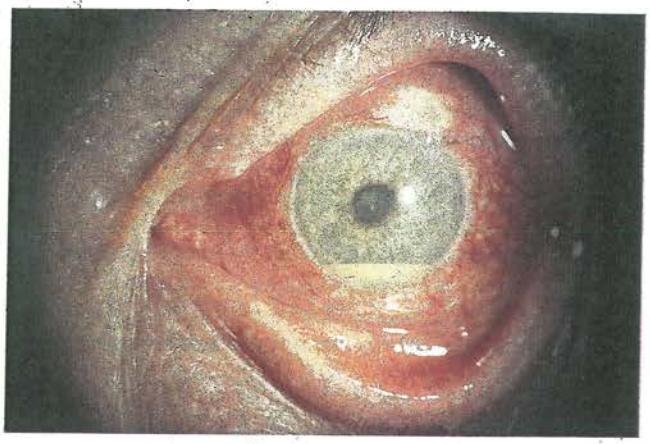

Figure 6.167 Severe endophthalmitis with hypopyon following trabeculectomy

Procedures that may possibly traumatize the bleb such as fitting of contact lenses or gonioscopy should be avoided if possible.

2. **Clinical features** vary according to the severity of infection and the presence or absence of vitreous involvement.
   (a) ***'Blebitis'*** is infection of the bleb without vitreous involvement. It is characterized by a whitened, milky bleb (Figure 6.166) that appears to contain inflammatory material. Presentation is with relatively mild symptoms which may be present for several days or longer.
   (b) ***Endophthalmitis*** has a much shorter history of rapidly worsening vision, pain and redness. Examination shows hypopyon (Figure 6.167) and impairment of the red reflex.
3. **Treatment** of 'blebitis' with systemic and topical antibiotics is usually adequate whereas fulminating endophthalmitis also requires intraocular antibiotics. As would be expected the prognosis for visual recovery is better in 'blebitis' than in endophthalmitis.

Failure of filtration

CLINICAL FEATURES

Following surgery the bleb may assume one of the following appearances:

1. **Type 1 bleb** has a thin and polycystic appearance due to a transconjunctival flow of aqueous and is associated with good filtration (*see* Figure 6.165).
2. **Type 2 bleb** is flat, thin and diffuse with a relatively avascular appearance in comparison with the surrounding conjunctiva (Figure 6.168). Conjunctival epithelial microcysts are usually visible with high magnification. This is also indicative of good filtration.

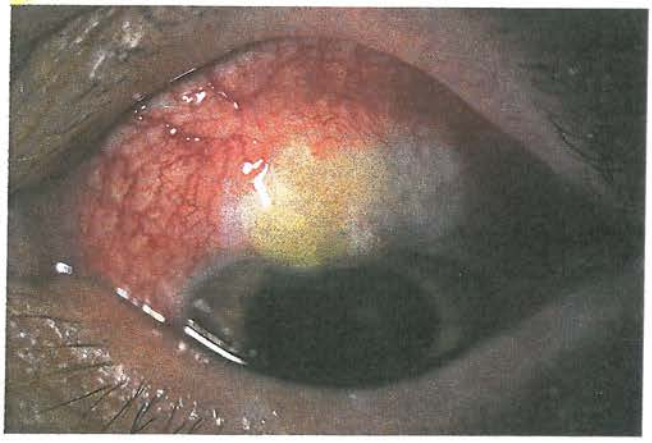

Figure 6.166 'Blebitis' following trabeculectomy characterized by a white drainage bleb with surrounding conjunctival injection

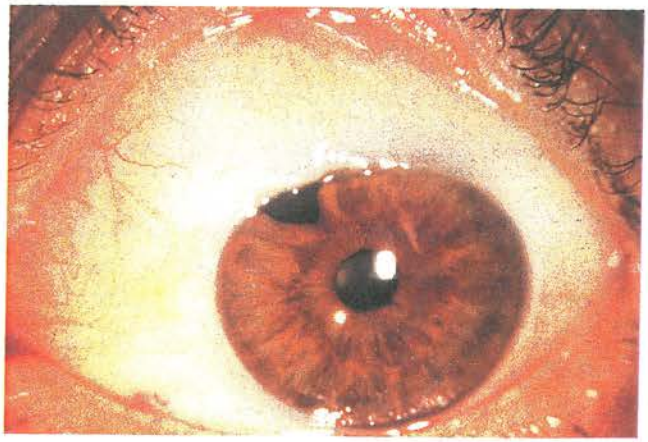

Figure 6.168 Thin, flat diffuse filtration bleb

3. **Type 3 bleb** is a non-filtering bleb caused by subconjunctival fibrosis. It is flat, unassociated with microcystic spaces and its surface contains engorged blood vessels (Figure 6.169).
4. **Encapsulated bleb** (Tenon capsule cyst) typically develops 2–8 weeks postoperatively. It is characterized by a localized, highly elevated, dome-shaped, firm, cyst-like cavity of hypertrophied Tenon capsule with engorged surface blood vessels (Figure 6.170). The cavity entraps aqueous humour and prevents filtration although in some cases the IOP may not be elevated because functional areas of filtration may surround the bleb.

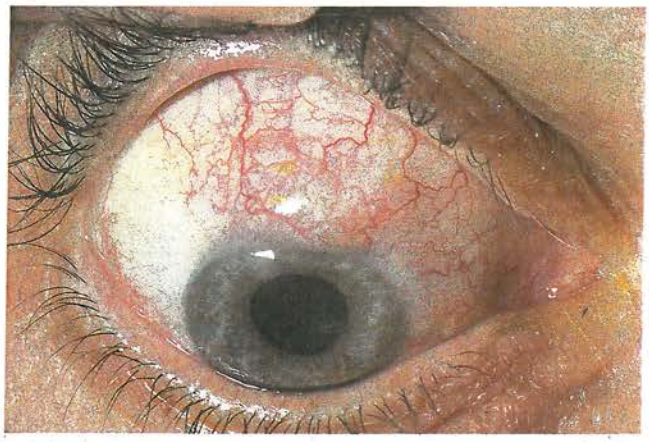

Figure 6.169 Vascularized non-filtering bleb

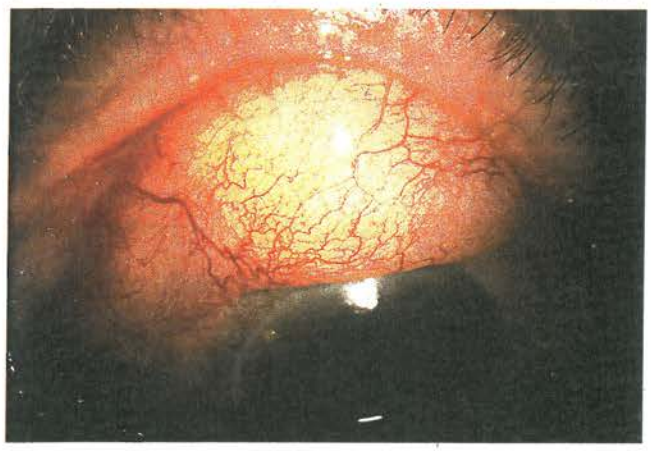

Figure 6.170 Encapsulated non-filtering bleb

FACTORS RELATED TO FAILURE

1. **Subconjunctival fibrosis** is the most common cause of bleb failure and in many cases a well-formed bleb is never established. The presence of subconjunctival blood may increase the risk of subsequent fibrosis and failure.
2. **Too tight suturing** of the scleral flap to the scleral bed or gradual scarring in the scleral bed may lead to obstruction of the fistula at that level.
3. **Obstruction of the internal opening** may occur by a variety of thin membranes derived from surrounding cornea or scleral tissue. This may be associated with poor surgical technique in which the opening is blocked by scleral remnants or by Descemet membrane.
4. **Blockage of the fistula** by vitreous, blood clot or uveal tissue.

MANAGEMENT OF FAILURE

Depending on the cause of failure, treatment may involve one or more of the following:

1. **Argon laser suture lysis** can be considered in the first 10–14 days postoperatively. The procedure can be performed either through a Hoskins suturelysis lens or with a Zeiss four-mirror goniolens. The laser settings are 0.2 sec duration, 50 µm spot size and a power of 500–700 mW.
2. **Digital massage** can be tried by applying firm pressure to the globe through the closed lower eyelid for 30 seconds four times a day.
3. **Topical steroids** can be instilled six to eight times daily to suppress the vascular ingrowth and inflammatory changes in the bleb.
4. **Subconjunctival injections of 5-fluorouracil** (5 mg daily) can be used in the first 7–14 days to suppress wound fibrosis.
5. **Nd:YAG laser** can, on rare occasions, be used to reopen a blockage of the internal opening of the fistula provided the tissue responsible can be identified gonioscopically and the eye already has a well-established bleb.
6. **Further surgery** may involve needling of a Tenon capsule cyst, a second filtering procedure or revision of the existing filter. In these cases the use of adjunctive antimetabolite therapy may be appropriate to increase the chances of a successful outcome.
7. **Medical therapy** may have to be recommenced if all else fails.

Adjunctive antimetabolites

INDICATIONS

Antimetabolite therapy should be used with great caution because of the serious nature of potential side-effects. This form of therapy should only be considered when known risk factors for failure of conventional trabeculectomy are present:

1. **Demographic risk factors** include black patients and those under the age of 40 years.

2. **Ocular risk factors**
   (a) Previous failed filtration surgery.
   (b) Previous cataract extraction with or without lens implantation.
   (c) Certain secondary glaucomas (e.g. inflammatory, post-traumatic angle recession).
   (d) Patients treated with topical antiglaucoma medication (particularly sympathomimetics) for over three years.

The success rate varies between 80% and 95% depending on the drug used.

GENERAL PRECAUTIONS

1. Antimetabolite therapy should be used with great caution when the conjunctiva has been recessed or where the limbal stem-cell population is decreased (e.g. alkali burns, ocular pemphigoid).
2. The filtration site should never be placed inferiorly because of the increased risk of late intraocular infection.
3. The antimetabolite must not come into contact with the edges of the conjunctival incisions or the corneal endothelium.
4. Tenon's capsule and conjunctiva should be sutured in two layers, using a round-bodied needle.
5. Patients should be warned of the potential late complications, in particular the high incidence of cystic bleb formation. They should be aware that additional surgery may be required in the event of late hypotony. Because of the potential for late bleb-related endophthalmitis they should be told of the risks associated with contact lens wear, swimming in a public pool and the danger of using contaminated drops.

5-FLUOROURACIL

5-Fluorouracil (5-FU) inhibits DNA synthesis and is active on the 'S' phase (synthesis phase) of the cell cycle. Fibroblastic proliferation is inhibited, but fibroblastic attachment and migration are unaffected. The drug can be used in the following two ways:

1. **Daily subconjunctival injections** of 5 mg for 5–7 days.
2. **Intraoperative application** is as follows:
   (a) Soak a small cellulose sponge in a 50 mg/ml solution of 5-FU.
   (b) Place the sponge at the site of filtration between the sclera and Tenon capsule making sure that the edges of the conjunctival incision are not exposed to the drug.
   (c) After 5 minutes remove the sponge and thoroughly irrigate with balanced salt solution.

MITOMYCIN C

Mitomycin C is an alkylating agent which selectively interrupts DNA replication, inhibiting mitosis and protein synthesis. The drug inhibits proliferation of fibroblasts and *in vitro* has been shown to be more potent than 5-FU. It also suppresses vascular ingrowth. Mitomycin C is only used at the time of surgery. The optimum concentration and exposure time is not known, although high concentrations and extended exposure times tend to be associated with an increased incidence of complications.

COMPLICATIONS

1. **Corneal epithelial defects** (Figure 6.171).
2. **A cystic thin-walled bleb** (*see* Figure 6.165) is a common complication which predisposes to: (a) chronic ocular hypotony (IOP <5 mmHg), (b) late-onset bleb leak and (c) endophthalmitis.

Figure 6.171 Corneal toxicity caused by 5-fluorouracil

ARTIFICIAL DRAINAGE SHUNTS

DEFINITION

Artificial drainage shunts are plastic devices which create a communication between the anterior chamber and sub-Tenon space. All of these shunts consist of a tube attached to a posterior episcleral explant. Some contain a pressure-sensitive valve for restriction of aqueous flow. Because of the many postoperative complications associated with this type of surgery, drainage shunts should be installed only by surgeons thoroughly trained in their use.

INDICATIONS

1. Uncontrolled glaucoma despite previous trabeculectomy with adjunctive antimetabolite therapy.
2. Glaucomas where routine trabeculectomy, with or without adjunctive antimetabolites, is unlikely to be successful. For example, active neovascular glaucoma, aniridia and glaucoma following traumatic anterior segment disruption.
3. Eyes with severe conjunctival scarring where dissection of the conjunctiva would be difficult.

IMPLANT TYPES

Most of the currently used filtration devices are based on the design originally described by Molteno, which incorporates a scleral explant to promote formation of a functioning bleb. An open tube placed into the anterior chamber shunts aqueous humour into an area of encapsulation around the explant located 10–12 mm posterior to the limbus. Reduction of IOP by these implants is due to passive, pressure-dependent flow of aqueous across the capsular wall. The magnitude of pressure reduction depends on the resistance to aqueous flow (the thicker the capsule, the higher the IOP) and the total surface area of encapsulation (the larger the surface, the lower the IOP). Some of the currently available implants are:

1. **Schocket**: silicone tube with a gutter extending for 360° around the globe (Figure 6.172**a**).
2. **Molteno**: silicone tube with single or double plates (Figure 6.172**b**).
3. **Krupin–Denver:** Silastic tube with slit valve on the end of the tube attached to a silicone oval disc (Figure 6.173).

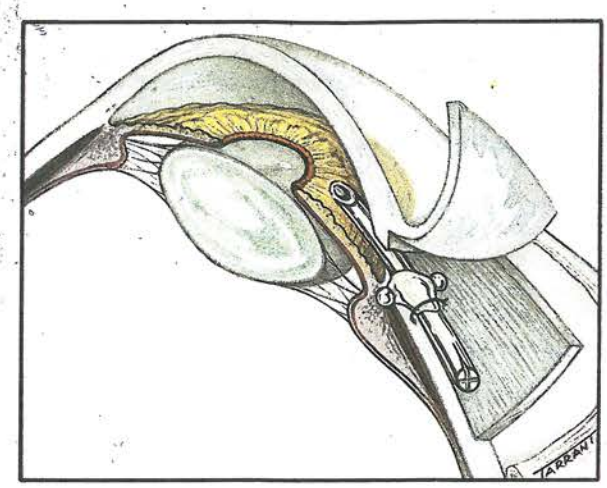

Figure 6.173 Krupin–Denver valve

COMPLICATIONS

Because shunts are used in severely damaged eyes the complication rate is higher than with conventional filtration surgery.

1. **Excessive drainage** may occur as a result of leakage around the tube or down the tube (Figure 6.174).
2. **Tube erosion** through the conjunctiva (Figure 6.175).
3. **Drainage failure** may occur as a result of blockage of the end of the tube by vitreous, blood or iris tissue.
4. **Bleb encapsulation** (Figure 6.176) over the footplate may develop with resultant poor drainage. This occurs in about 10% of cases and is the most significant late complication.

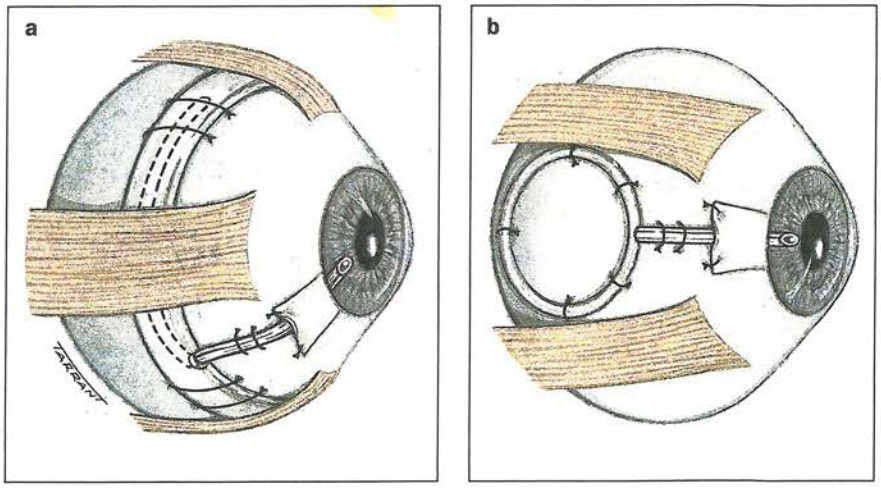

Figure 6.172 Artificial shunts. **a**: Schocket tube and gutter; **b**: Molteno implant

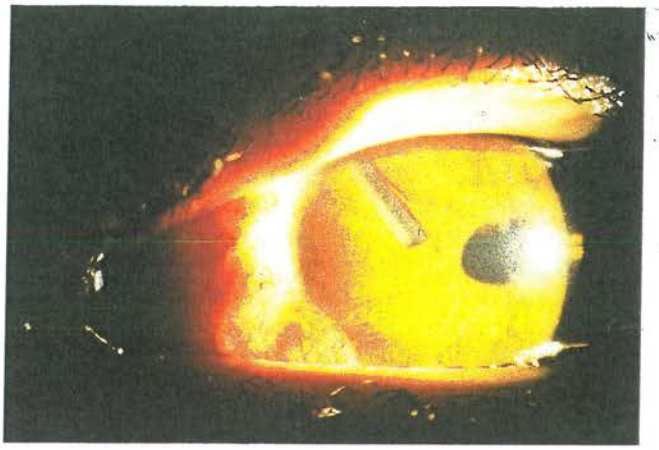

Figure 6.174 Flat anterior chamber secondary to excessive drainage

Figure 6.175 Erosion of tube through the conjunctiva

Figure 6.176 Encapsulation of the bleb over the footplate

RESULTS

The success rate for IOP control depends on the type of glaucoma and the length of follow-up and is similar for all types of implants. In general, an IOP <21 mmHg is achieved in 50–70% of cases but topical medication is often required to maintain the IOP at this level. Less than 33% of cases have controlled IOP without the use of additional medical therapy. The long-term success rate in neovascular glaucoma is particularly disappointing because of progressive retinal disease with loss of vision and late development of phthisis bulbi.

CYCLODESTRUCTIVE PROCEDURES

Cyclodestructive procedures lower IOP by destroying part of the secretory ciliary epithelium thereby reducing aqueous secretion. They are used mainly to control intractable glaucoma, usually associated with permanent synechial angle closure, which has failed to respond to other measures aimed at increasing aqueous outflow. The three currently used procedures are: (a) ***cyclocryotherapy*** (Figure 6.177), (b) ***Nd:YAG laser cyclodestruction*** (Figure 6.178) and (c) ***diode laser cyclophotocoagulation.***

COMPLICATIONS

Because the main aim of these procedures is usually to relieve pain in an otherwise blind eye, vision-threatening complications do not have the same significance as those following conventional filtration surgery.

1. **Chronic hypotony** occurs in about 5% of cases because the facility of outflow in many eyes is so seriously impaired that only a slight reduction of aqueous inflow tips the eye into hypotony. In neovascular glaucoma the incidence of subsequent phthisis is about 40%.
2. **Anterior segment complications** include scleral thinning and cataract formation.

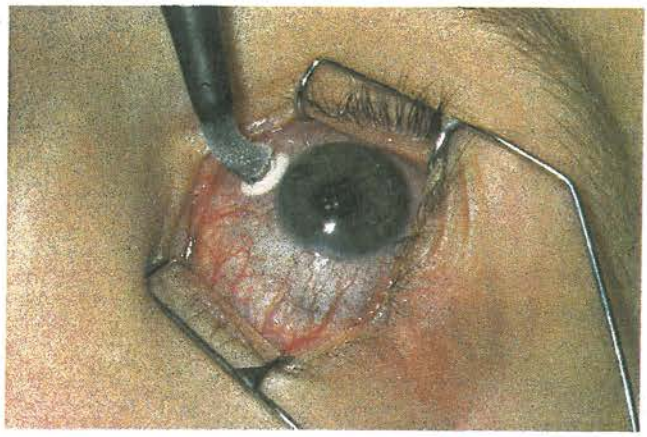

Figure 6.177 Position of the probe during cyclocryotherapy

Figure 6.178 Appearance of the conjunctiva following Nd:YAG laser transscleral cycloablation

3. **Posterior segment complications** include haemorrhage, chronic macular oedema and unexplained loss of vision.

RESULTS

In general cyclodestructive procedures afford long-term control of pain without good pressure control in various types of glaucoma. Pain relief does not appear to be solely related to pressure control. In childhood secondary inflammatory glaucoma the long-term success rate is very low, presumably due to the fact that the secretory ciliary epithelium is more resistant to damage.